

CD

**BASIC
PRINCIPLES**

OF THE COTREL
DUBOUSSET INSTRUMENTATION

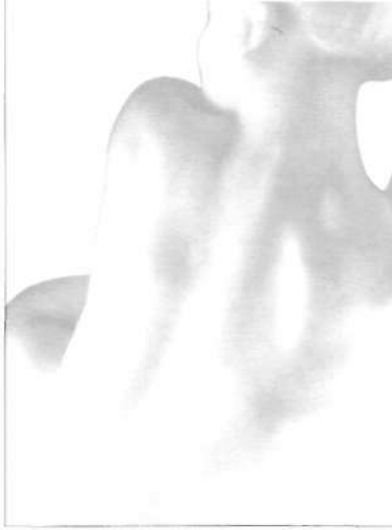CONCEPT AND TECHNIC

Y V E S C O T R E L

This booklet is intended to meet the needs of surgeons who have heard the oral presentation of "Basic Principles of Cotrel-Dubousset Instrumentation" and to provide illustrations for the better understanding of these basic principles.

This presentation is necessarily diagrammatic and incomplete. This is not intended to provide the only method of use of C.D.I., nor excuse inexperienced surgeons from learning from other surgeons with greater experience. It is necessary that courses organized by scientific societies, e.g., G.I.C.D., Scoliosis Research Society, etc... be attended to achieve minimum preparation for C.D.I. prior to using it. I hope that this booklet will be interesting and informative.

DUCTION



P 7

THE CD RANGE

P 8

THE BASIC PRINCIPLES OF
COTREL-DUBOUSSET INSTRUMENTATION

P 11

CORRECTION

P 12

FIXATION

P 16

CORRECTION OF A 3-D DEFORMITY

P 19

HOW TO PREPARE THE PREOPERATIVE PLAN ?

P 20

WHICH ARE THE STRATEGIC VERTEBRAE (S.V.)
OF A SCOLIOTIC CURVE ?

P 20

WHAT DETERMINES THE
STRATEGIC VERTEBRAE (S.V.) ?

P 31

WHAT IS THE DIRECTION FOR
APPLICATION OF FORCES ?

P 32

WHICH SIDE MUST BE APPROACHED
FIRST, CONCAVE OR CONVEX?

P 35

ARE THERE
ALTERNATE POSSIBILITIES?

P 36

SPECIAL SITUATIONS

P 44

TEN TECHNICAL GUIDELINES FOR USE
OF THE C.D. IN SCOLIOSIS

P 48

APPROACH TO A SINGLE
DIMENSIONAL DEFORMITY

P 51

LONG THORACIC KYPHOSIS OR
THORACOLUMBAR KYPHOSIS

P 55

SHORT DEFORMITIES IN KYPHOSIS


P 63

CONCLUSION

P 64

STRATEGIC MISTAKES

CONTENTS



The C.D. range

C.D. implants - hooks and screws - constitute the elements

for a posterior fixation of the spine. All implants are designed with either closed or open bodies (open implants require a blocker to be closed).

There are several vertebral placement sites for hooks. Pedicle hooks are placed under the pedicle through the facet joint. This is possible in the thoracic spine distally to T-10 or T-11, depending upon the anatomy. Laminar hooks can be placed in either supra or infra laminar position, as well as on the transverse process.

Screws are either vertebral or sacral. Their use should be confined to the lumbar spine, or sacrum.

The rods are the support of the implants. They allow their

loading at any level and in any direction ; the bending of the rods make possible the 3D mobilization of the instrumented vertebrae.

The Device for Transverse Traction assures joining

of the rods and solid fixation of the construct.

With **the connection components** (domino, connecting tube),

the CD Instrumentation allows various constructs to be made.

The basic principles of Cotrel-Dubousset Instrumentation,

as initially devised for the treatment of spinal deformity (scoliosis and kyphosis) hold true for the treatment of any spinal problem requiring internal fixation: deformity, trauma, instability, and reconstruction.

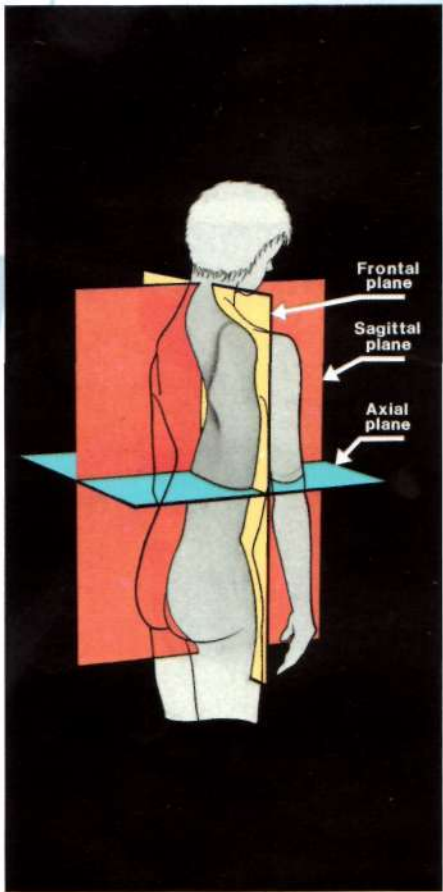
The spine must always be visualized as a three dimensional structure, with deformity in the frontal, sagittal, and axial planes. (1)

In scoliosis, the sagittal deformity is as, if not more, important to consider than the coronal deformity. In the sagittal plane, the thoracic spine is usually relatively or absolutely lordotic. The lumbar spine is, conversely, relatively or absolutely kyphotic. The sagittal curves are frequently reversed from their normal alignment. The maximum axial deformity is usually at the apex of a single frontal curve (2) or at the junction-point of two major curves.

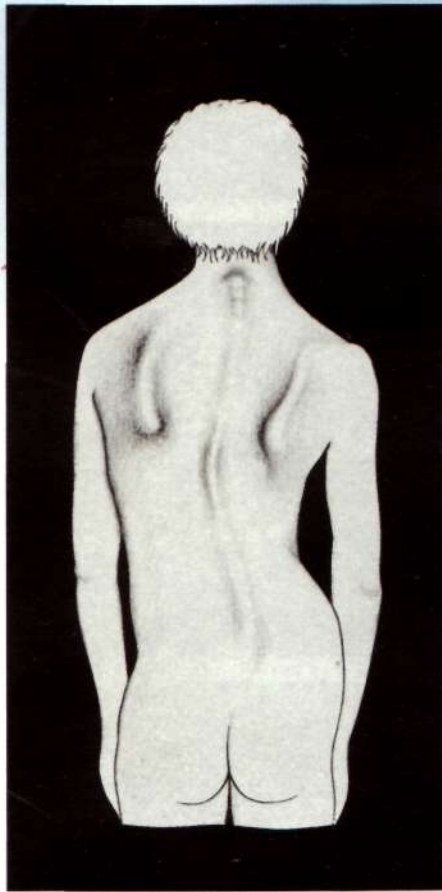
Correction with C.D. demands visualization in the three dimensions, simultaneously. The terms distraction and compression in their usual meaning must be forgotten. One must be familiar to consider these words only in terms of the direction in which the forces are to be applied (force direction).

The concepts of C.D. include: frontal correction, sagittal normalization, apical derotation. These events happen simultaneously, due to the biomechanical action of C.D.

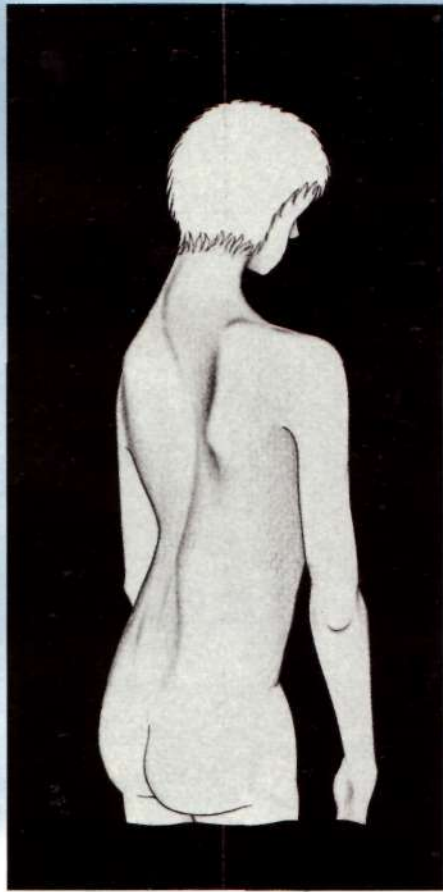




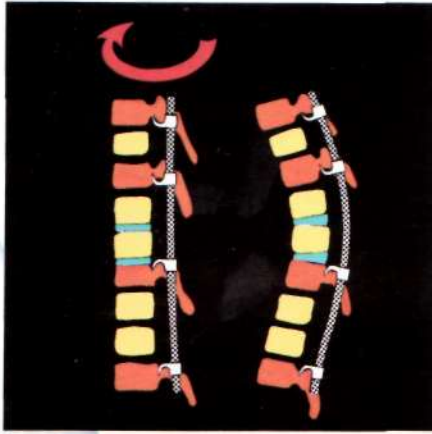
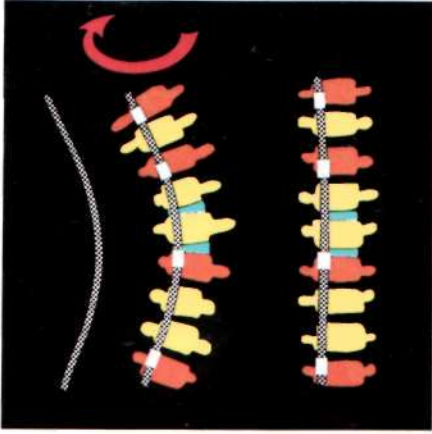
1



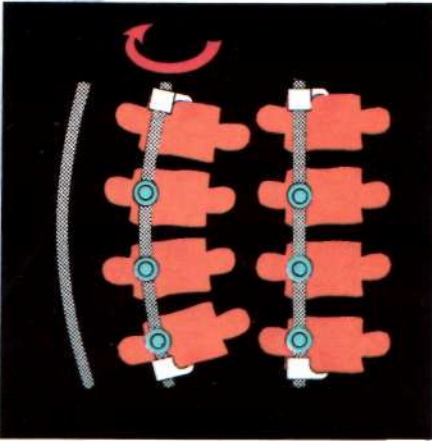
2



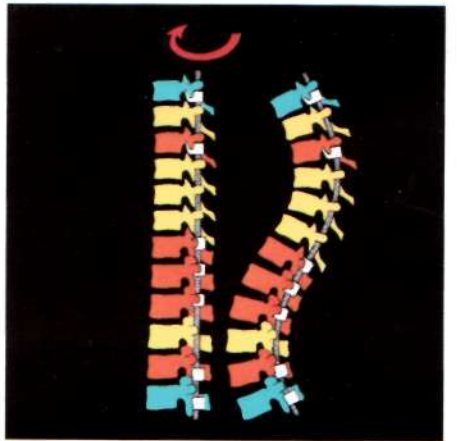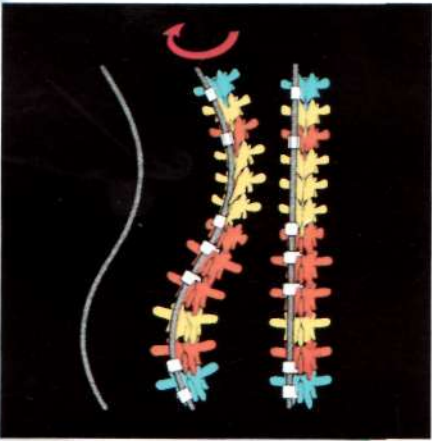
3a



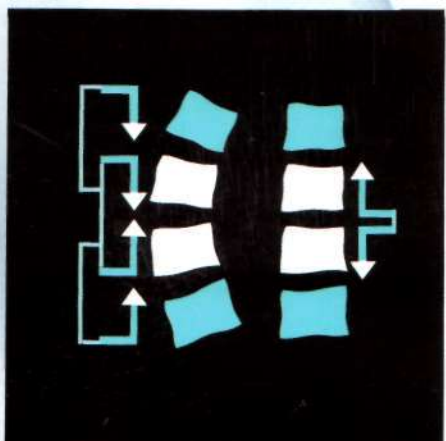
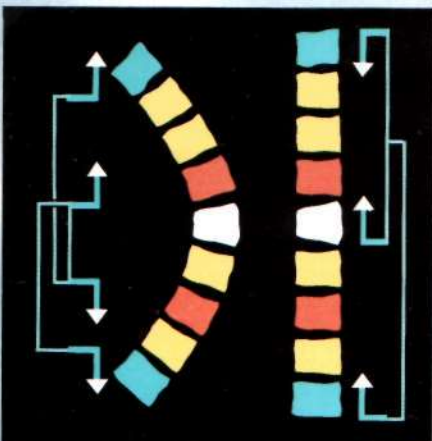
3b



4



5



Correction

After selection and instrumentation of the “strategic vertebrae” (S.V.), 3-D correction is achieved by two successive maneuvers:

1. By rotation of a rod bent to normal sagittal contours

in the implants (hooks or screws). (3) Initial concave placement is required to correct a lordosis.

Initial convex placement of the instrumentation is required to correct a kyphosis.

Compliance with these basic ideas will allow reconstruction of the sagittal plane in any situation accompanying frontal and axial correction. The best example is the double curve scoliosis. (4)

2. By loading the implants inserted on the S.V., either

in distraction direction (spreading) **or compression** (approximation) (5).

It concomitantly corrects the segmental deformities and horizontilizes the end vertebrae (E.V.) in the frontal plane.

These two maneuvers do not produce any significant spinal elongation.

Fixation

Mechanical requirements involve the following points:

Rod-implant fixation. (6)

This is achieved by set screws, which at first are tightened as position of the implants is not definitive. Finally, the set screws are broken, affording excellent rod-implant fixation. An infinite number of adjustments are possible.

A rectangular construct in the frontal plane.

The Device of Transverse Traction (D.T.T.) allows either spreading or approximation of the two rods, which increases the stability of the hooks on the site of their implantation.

The rods are approximated at the level on the pedicular hooks or pediculo-transverse grip to prevent their lateral displacement.

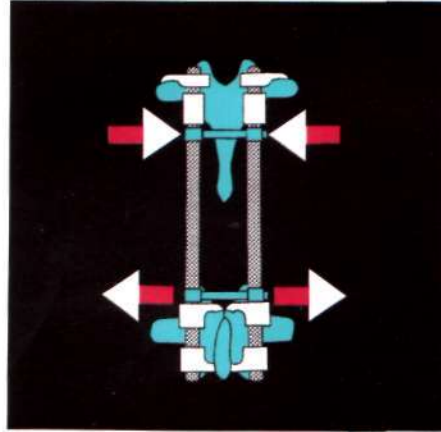
They are spread at the level of the laminar hooks to prevent their medial displacement inside the canal. (7)

It creates a rigid frame interlocking all the implants. A construct over 30 cm requires three DTT devices for optimal biomechanical rigidity. Less than 30 cm requires a minimum of two DTT devices.

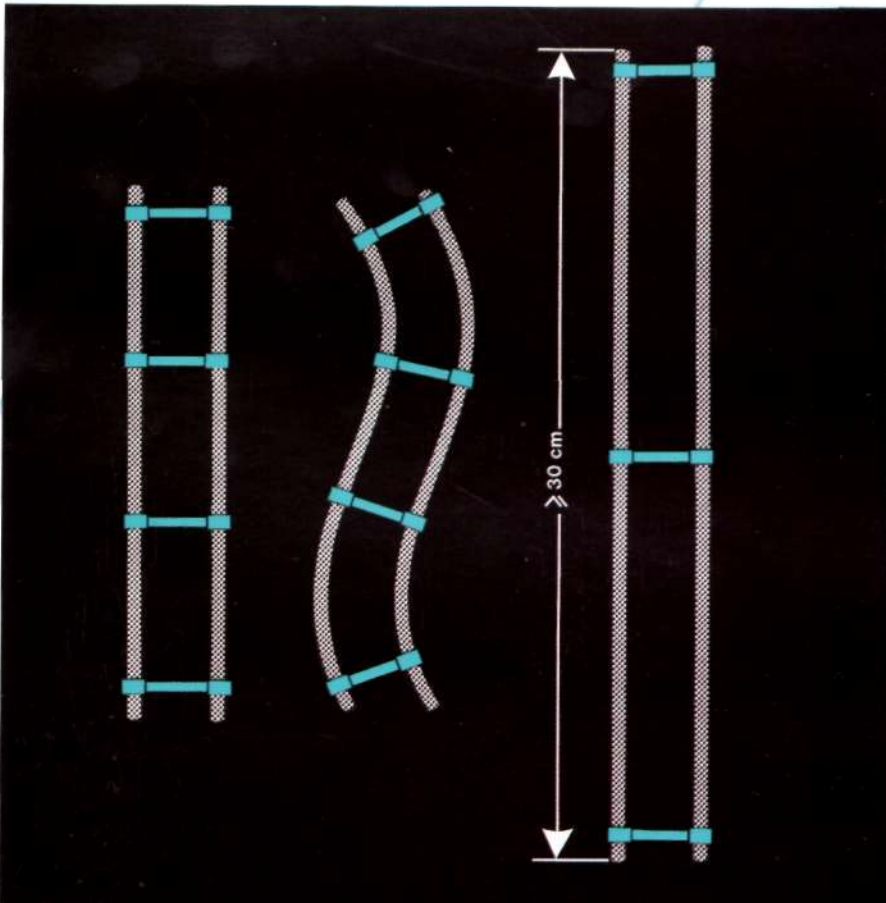
The frontal rectangle provided by the rods and DTT devices allows for considerable resistance to the strain forces in the three dimensions, particularly, the torsional strain. The result is the exemption of any postoperative support in most instances. (8)



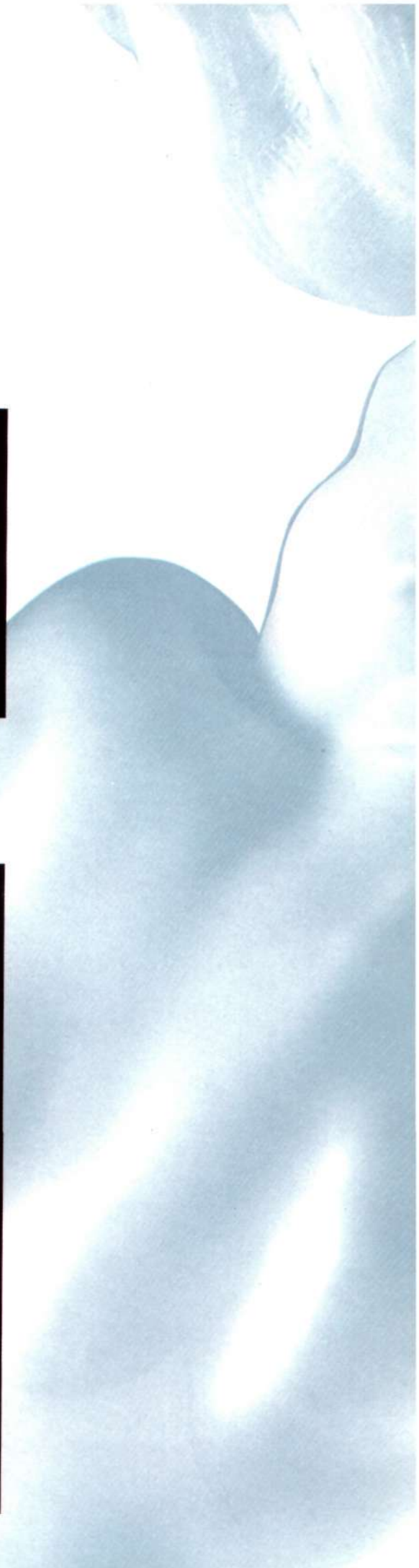6

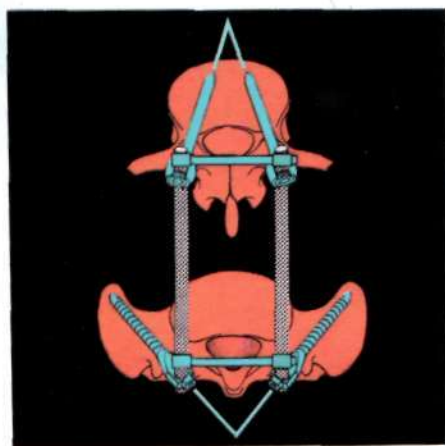
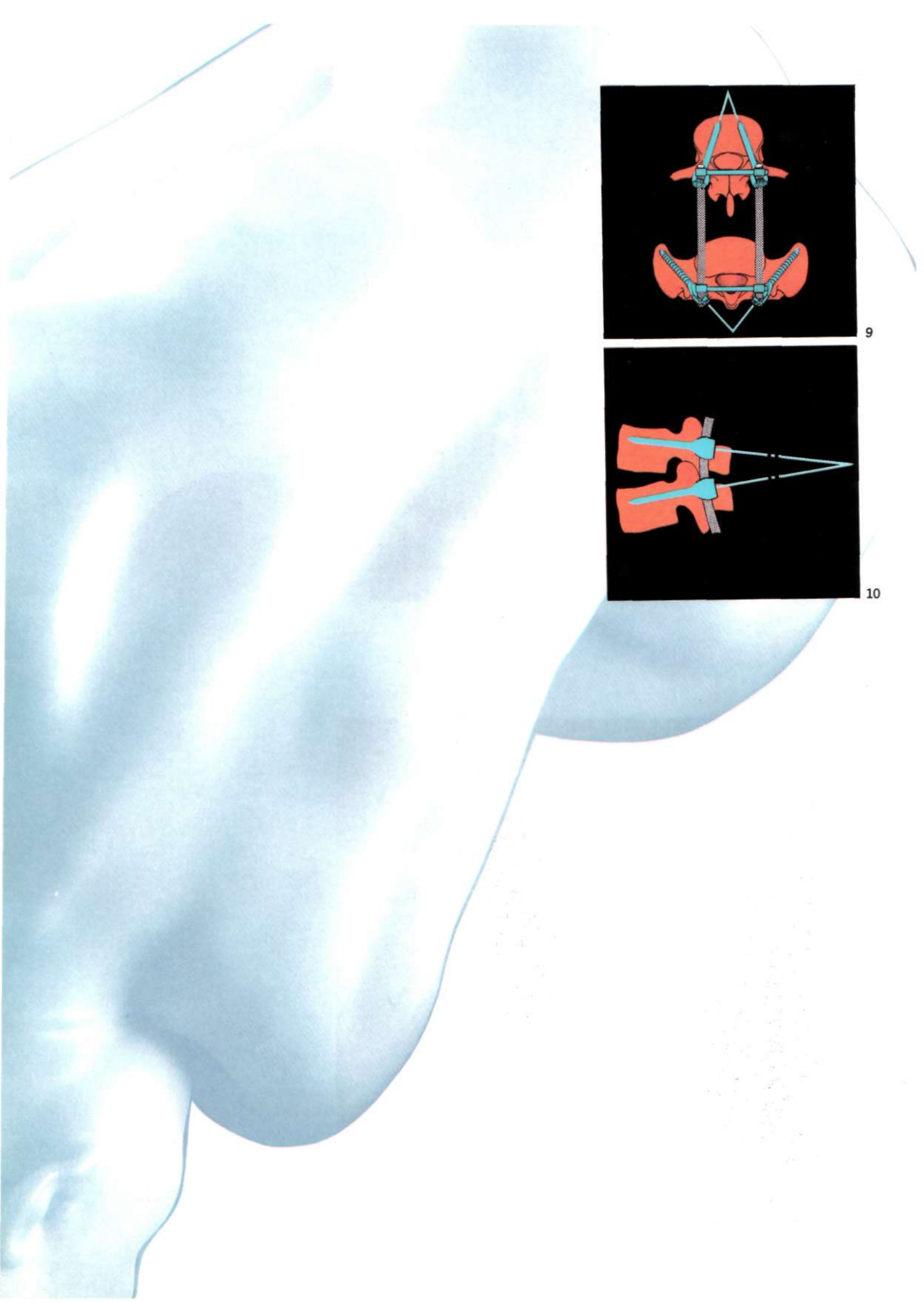


7

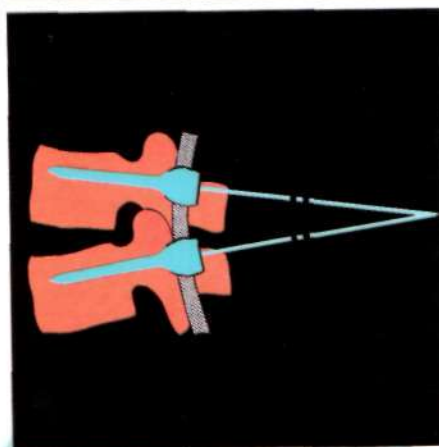


8





9



10

A triangular construct in the axial plane.

At the lumbar and sacrum levels, it is achieved by the rigid posterior linkage with the DTT or the Chopin plate and two screws forwardly convergent or divergent, implanted on each side of a lumbar vertebra or of the sacrum. It prevents the pull-out of the screws and affords a very strong and stable bone fixation, allowing vertebral selective immobilization in the axial plane and the detorsion of the lumbar spine. (9)

A triangular construct in the sagittal plane.

The correction of the lumbar lordosis with the bending of the rod produces a triangular configuration of the construct in the sagittal plane. (10)

This geometrical construct that also prevents the pull-out of the screws, contributes to increase strength and stability of the bone fixation.

CORRECTION OF A 3-D DEFORMITY

The goal of C.D. Instrumentation is:

To obtain a balance in the three dimensions of space in all areas of bodily function, sitting, standing, and mobility.

First, consideration of treatment of the most complex deformities, the three dimensional one will be considered (11). Subsequently, other areas of spinal pathology will be addressed.

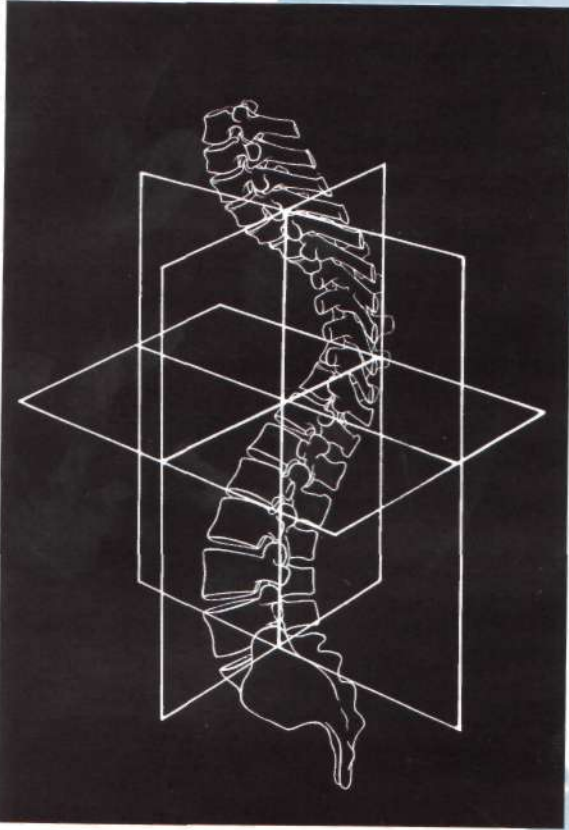
Complete, or as complete as possible, correction of a curve is not necessarily the optimum solution.

If possible, complete correction of a thoracic scoliosis in the frontal plane may result in trunk and shoulder imbalance (12) if the compensatory curves have not the necessary flexibility to balance the corrected thoracic curve; this flexibility can only be determined on the pre-operative lateral bending films.

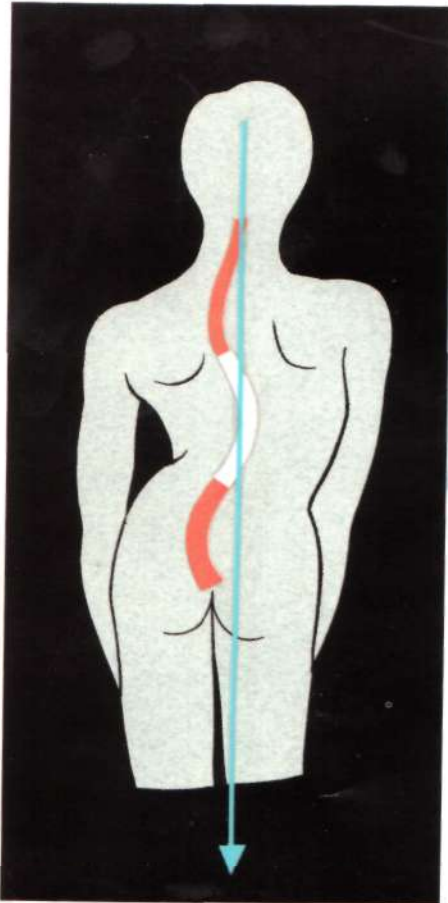
This principle must always be kept in mind.

With C.D.I., it is not necessary to instrument every vertebra in the curve. But, it is mandatory to identify and instrument some specific vertebrae, called "Strategic Vertebrae" (S.V.), and to mobilize them by segmental actions to obtain the maximum correction of the deformity, compatible with spinal balance in all the planes.

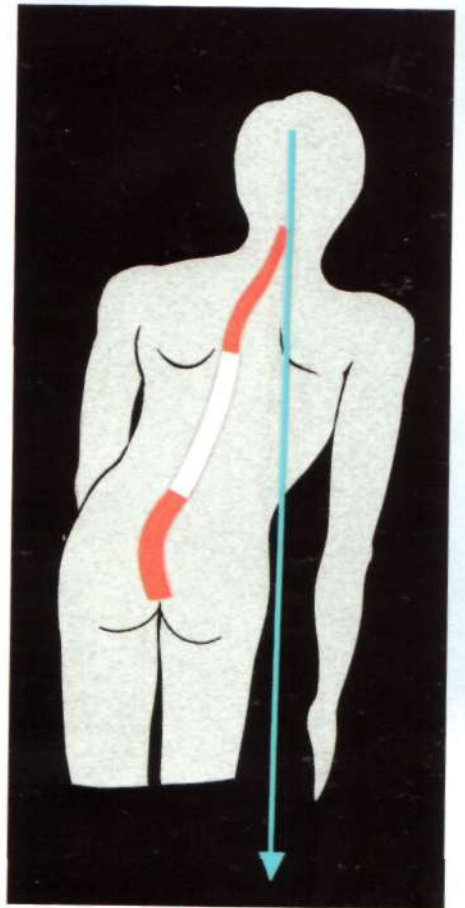
The preoperative planning is then of major importance.



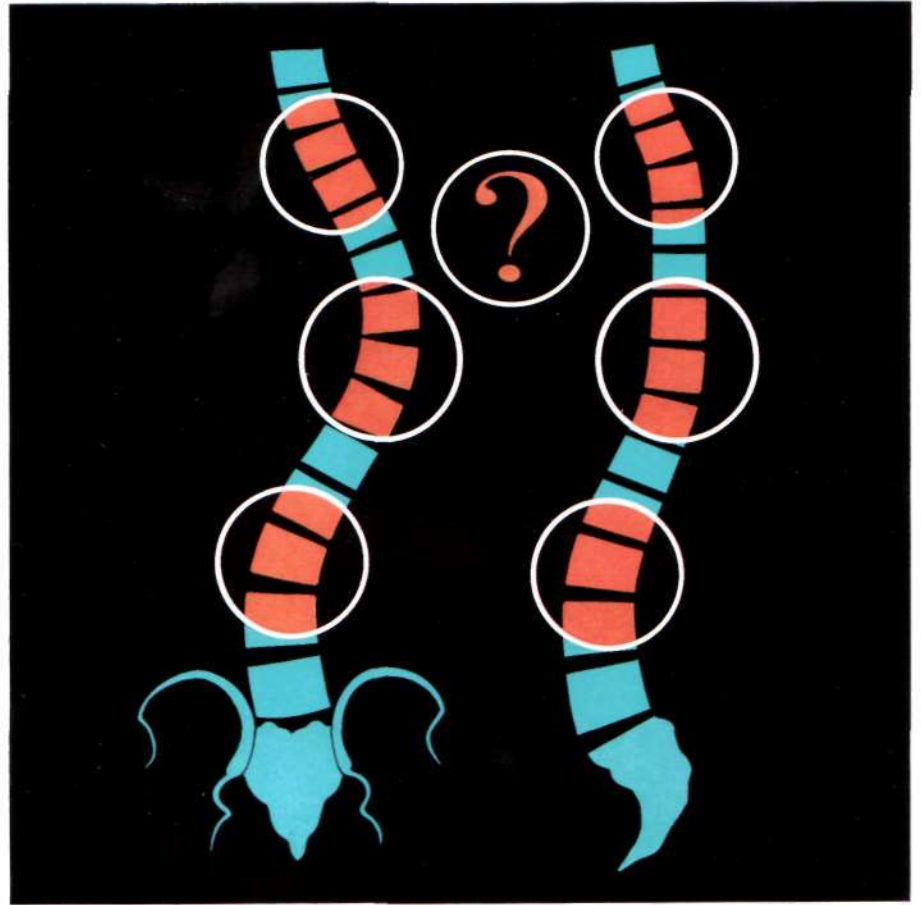
11




12a



12b



13



14



How to prepare the preoperative plan?

Several questions arise:

1. What are the strategic vertebrae (S.V.) of a scoliotic curve?
2. What determines the S.V.?
3. What is the direction of application of forces?
4. Which side must be instrumented first?
5. Are there alternate possibilities?

*Which are the strategic vertebrae (S.V.)
of a scoliotic curve?*

They are:

- the Apical Vertebra (A.V.),
- the Neutral Vertebrae (N.V.), upper and lower,
- the Intermediate Vertebrae (I.V.), upper and lower,
- the End Vertebrae (E.V.), upper and lower of the area to be instrumented.

What determines the strategic vertebrae (S.V.)?

Radiographic evaluation gives the answer.

Required radiographic studies always include:

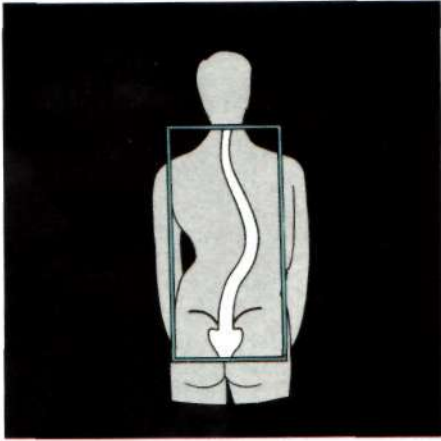- The standing AP film (15), that determines the Apical Vertebra (A.V.) and the Neutral Vertebrae (N.V.),
- The standing lateral film (16), that determines the final End Vertebrae (E.V.), of the area to be instrumented,
- The supine bending films, right and left, that determines the Intermediate Vertebrae (I.V.) (17).

Radiographic studies occasionally required:

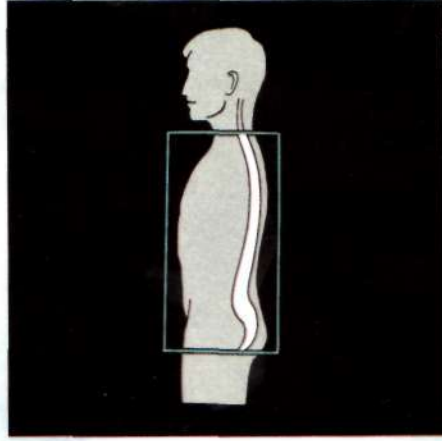
- The supine lateral film in flexion and extension, sometimes on a billot, that allows to estimate the possible reduction of the sagittal deformity (lordosis, kyphosis),
- The traction film, that allows to estimate globally the possible correction of the various curves compatible with the trunk balance.

Vertebral movement and disc movement must be noted on all films as their positions change in the three dimensions (18).

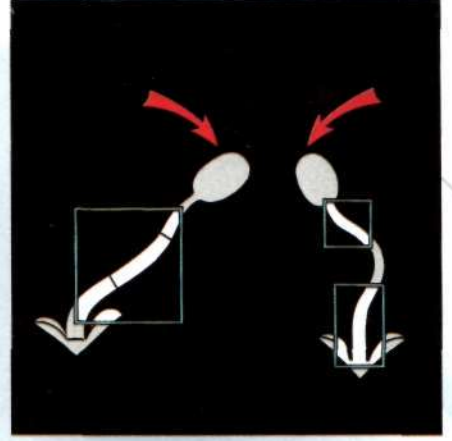
15



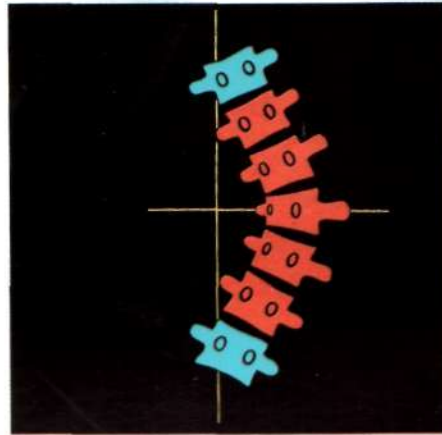
16




17

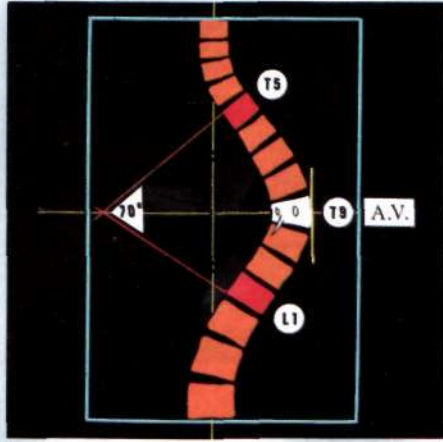


18a

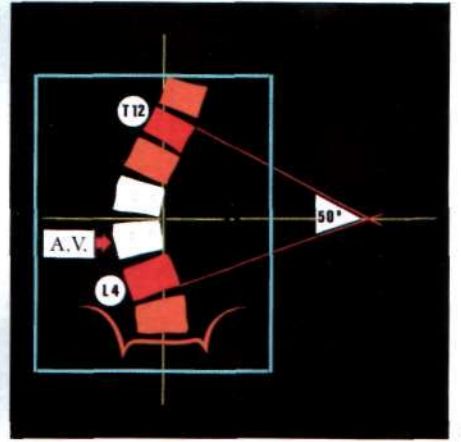


18b






19a



19b



20

Begin with defining the apical vertebra, then the neutral vertebrae, the intermediate vertebrae and finally the end vertebrae of the C.D. construct.

1) The Apical Vertebra (A.V.) (19)

On the standing AP film, the A.V. is:

- the most horizontal,
- the most rotated,
- the most deformed (cuneiform),
- the most deviated from the vertical axis, its lateral edge is perpendicular to the floor (parallel to the side of the film).

Note: in the lumbar spine, the apical area is, frequently, a disc space. In that case, the lower vertebra is considered as the A.V.

2) The Neutral Vertebrae (N.V.) (20)

On the standing AP film, the N.V. are:

- the most tilted (they allow to measure the Cobb angle),
- usually neutrally rotated,
- very near to vertical axis, or center sacral line (King classification).

Compensatory curves, either functional or structural, begin here.


3) The Intermediate Vertebrae (I.V.)

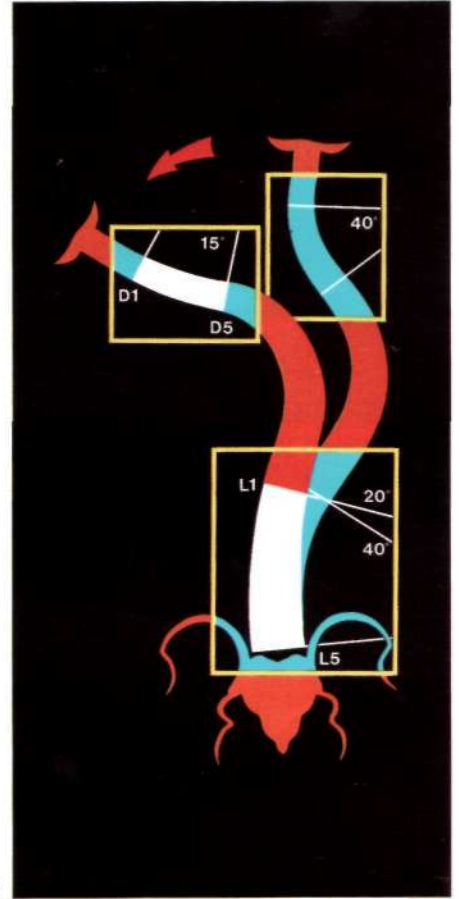
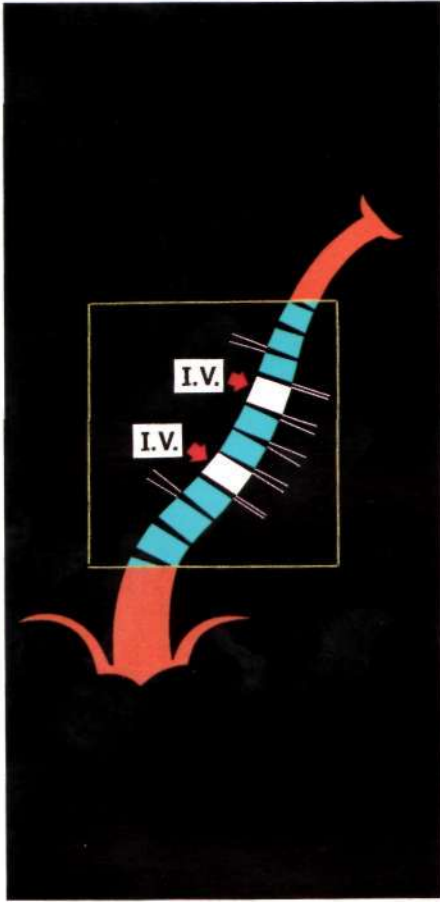
The Supine bending films, right and left, reveal the flexibility of the curve(s), and the rigidity of each intervertebral space, in the frontal plane.

Maximum rigidity is periapical and decreases toward the end(s) of the curve(s).

The upper and lower vertebrae of the most rigid segment on the bending film towards the convexity constitutes the I.V. (21). This, in thoracic curves, corresponds generally to the lordotic segment.

Bending film towards the concavity determine the extent and the severity of the structural or functional compensatory curves, and show the limits of their spontaneous correction (22).

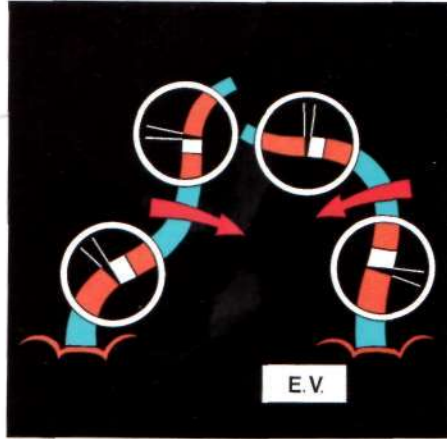




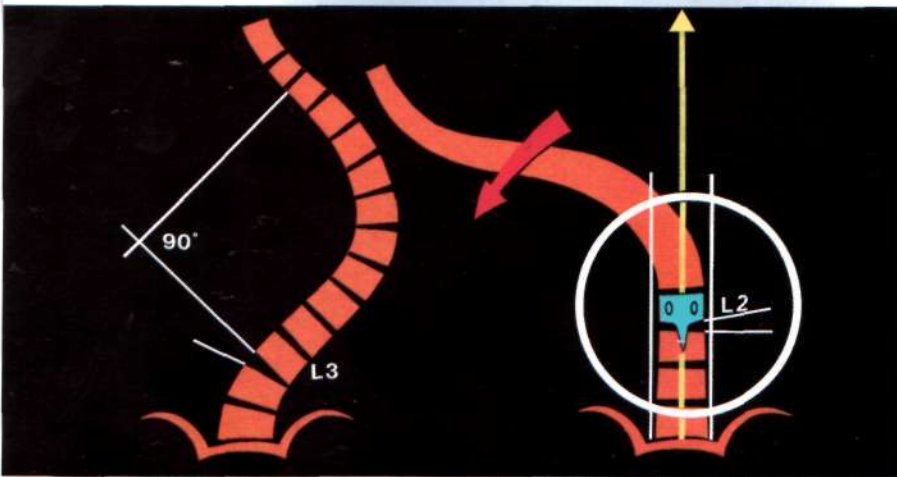
23 a



23 b



24



4) The End Vertebrae (E.V.) of the instrumentation

Four films are required to determine the E.V.:

- the standing AP film,
- the two supine bending films (right and left),
- the standing lateral film.

The definition of the E.V. is the most common area of errors in C.D. planning. These errors are the principal reason of post-operative decompensation. These vertebrae must be very carefully defined.

Standing A.P. film

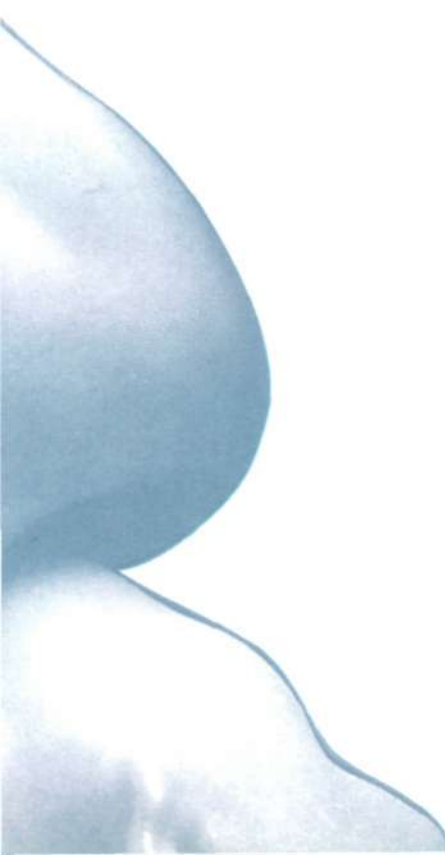The N.V. must be included in the instrumentation. In a mature patient, some residual rotation can be tolerated at the L.E.V. level (23a).

Supine bending films

The disc that opens in both bending films can be left outside of the instrumentation area (23b). This applies to both U.E.V. and L.E.V. at the condition that the standing lateral film confirms this choice. If not, the standing lateral film takes precedence on the bending films.

The L.E.V. must fall within the stable zone of Harrington or be bisected by the center sacral line of King.

When utilizing the bending films relative to the stable zone, frequently one or more levels will be saved as compared to the selection based solely on the standing AP film (24).



Standing lateral film

Absolute determination of the E.V.

The segmental sagittal analysis of each vertebra and each disc space must be done very carefully, and any variance from normal segmental sagittal anatomy noted (25). Any sagittal plane abnormality must be included in the fusion area.

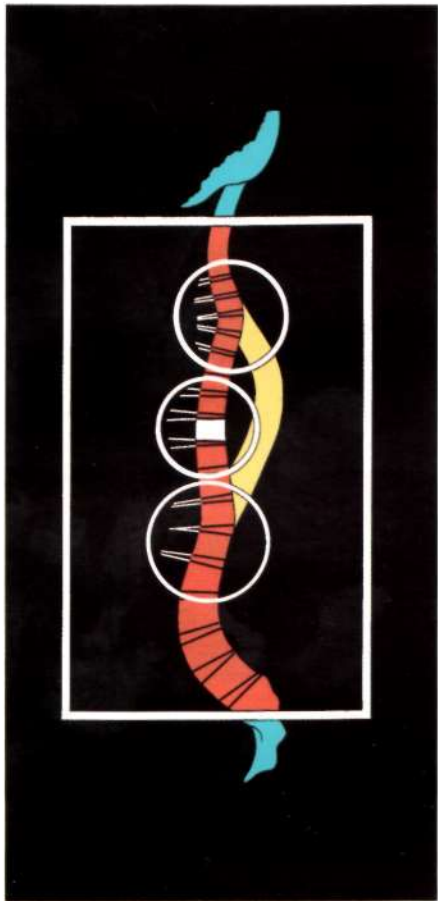
If not, these abnormalities at the end of the frontal curves will most likely lead to sagittal imbalance.

In the example (26), T-5 and L-1 are the limits of the curve in the frontal plane, but in the sagittal plane, T-3 and L-2 are in an abnormal position. They must be included in the instrumented area.

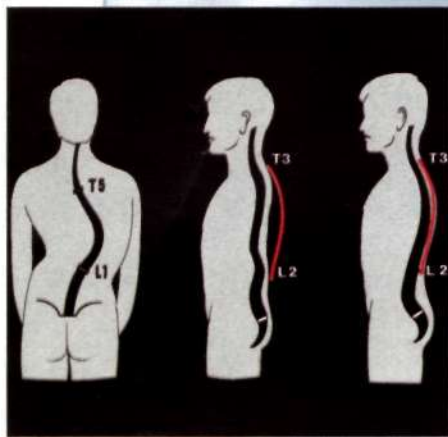
This addition to the fusion levels is the only manner in which the sagittal plane can be harmonious, and postoperative sagittal plane decompensation can be prevented.

In the lumbar spine, if the distal end of the sagittal deformity (L-2 in this example) corresponds to a vertebra which presents an absolute structural rotation on the A.P. film the instrumentation must be extended to the rotationally neutral vertebra (L-3) (27).

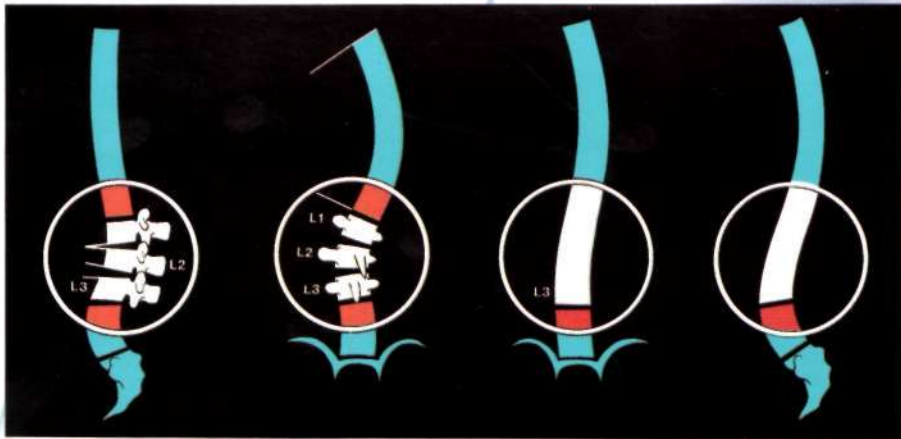
The disc space, distal to the L.E.V., must move normally in every plane, but most importantly in the sagittal plane, to preserve long-term functioning of the lumbar spine (28).



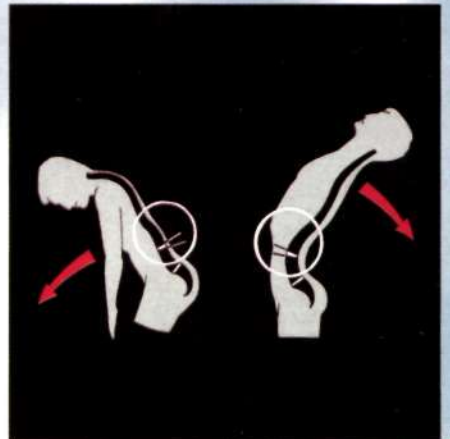
25



26



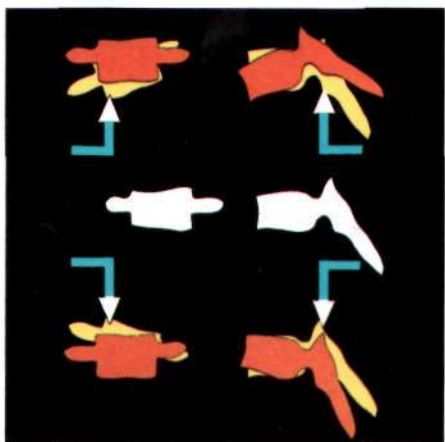
27




28



29



30



What is the direction for application of forces?

The forces generated by C.D.I. are very powerful.

Improper application of C.D. forces can lead to imbalance, and can result in neurologic injury.

Forces always must be designed to open closed I.V.S. and to close open spaces (29).

This concept is simple and fundamental; it must never be forgotten.

Distraction direction forces (away from the apex) always produce absolute or relative kyphosis.

Compression direction forces (toward the apex) always produce absolute or relative lordosis (30).

*Which side must be approached first,
concave or convex?*

Thoracic lordoscoliosis (31):

Concave side first.

Concave hooks divergent from apex.

Convex hooks convergent to apex.

Concave rod rotated outwardly from concavity.

Thoracic kyphoscoliosis (rare occurrence):

Convex side first.

Convex hooks convergent to apex.

Concave hooks divergent from apex.

No rod rotation, but maneuvers of approximation of all the convex hooks toward the apical vertebra, as for a kyphosis.

Lumbar scoliosis (with or without lumbar absolute or relative

kyphosis) (32):

Convex side first.


Convex hooks or screws convergent to apex.

Concave implants divergent from apex.

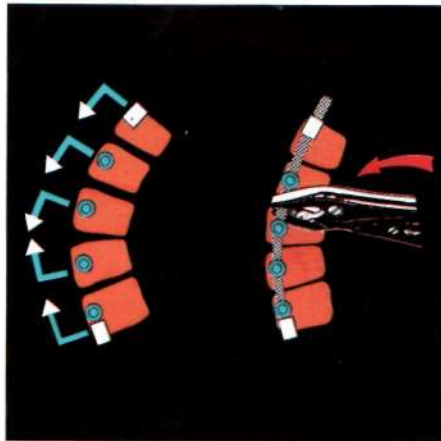
Convex rod rotated inwardly from convexity.

Rod rotation may not be always possible then the correction maneuvers must be as for a thoracic kyphoscoliosis.






31



32





If the instrumentation of a thoracic deformity must be extended into the lumbar spine, it is mandatory to initiate a lordotic rod bent at the thoracolumbar junction to induce lordosis. Compress the convex side of the lumbar segment first.

This is necessary for two reasons:

1) Lordosis can only be induced from the convex side. It is impossible to induce lordosis from the concave side.

Lordosing or compression direction forces, applied from the concave side will only increase the frontal deformity.

2) Open I.V.S. must never be instrumented in a direction to open these spaces more.

This can only result in imbalance.

Are there alternate possibilities?

Yes.

It is essential to have always in mind the above principles but obviously the preoperative plan must be adapted to each deformity.

Special situations:

Flexible (or made flexible by release procedures) **thoracic or thoracolumbar scoliosis.** (33)

Rod rotation corrects the frontal plane deformity. Translating medially and posteriorly the apical areas, it produces spinal detorsion.

All spinal traction, internal or external, must be removed prior to rod rotation. All set screws must be loose.

Rigid and large deformities in coronal or sagittal plane

(thoracic or thoracolumbar curves).

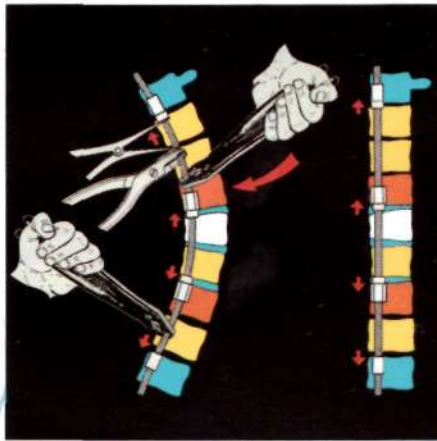
Work the concave side first with 2 rods.

The first, a short rod is inserted over the apical segments between the I.V. This bent rod will be rotated.

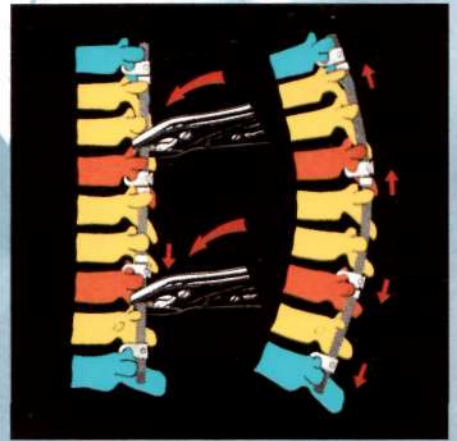The second concave rod inserted between the E.V. must be also bent and rotated to increase the correction, if needed (34).

The two rods are then connected and approximated by one or two D.T.T. devices. Additional correction is gained and the stability of the vertebral grip is increased (35).

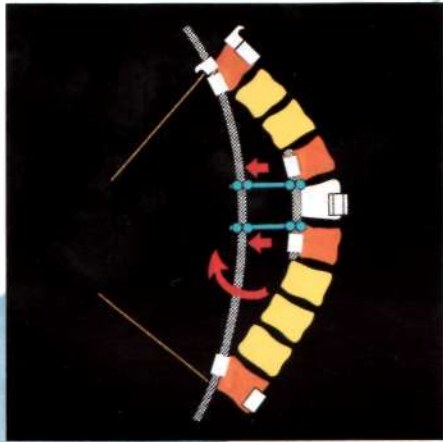
It is necessary to place a pediculo-transverse claw on the U.E.V. to prevent displacement of the pedicular hook during rod manipulation(36).



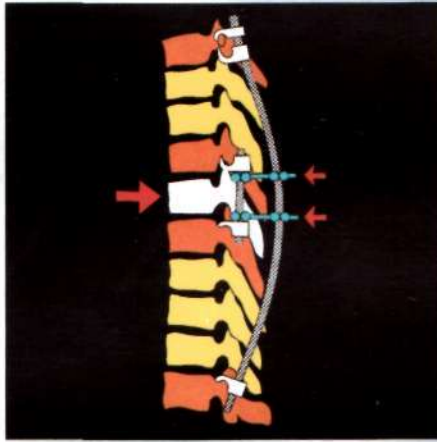
33a




33b



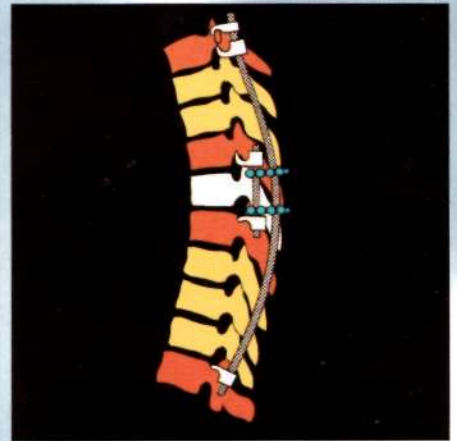
34a



34b



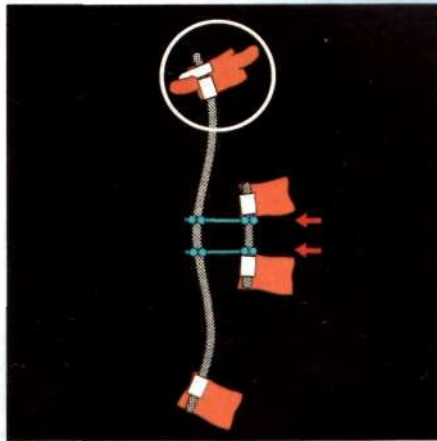
35a



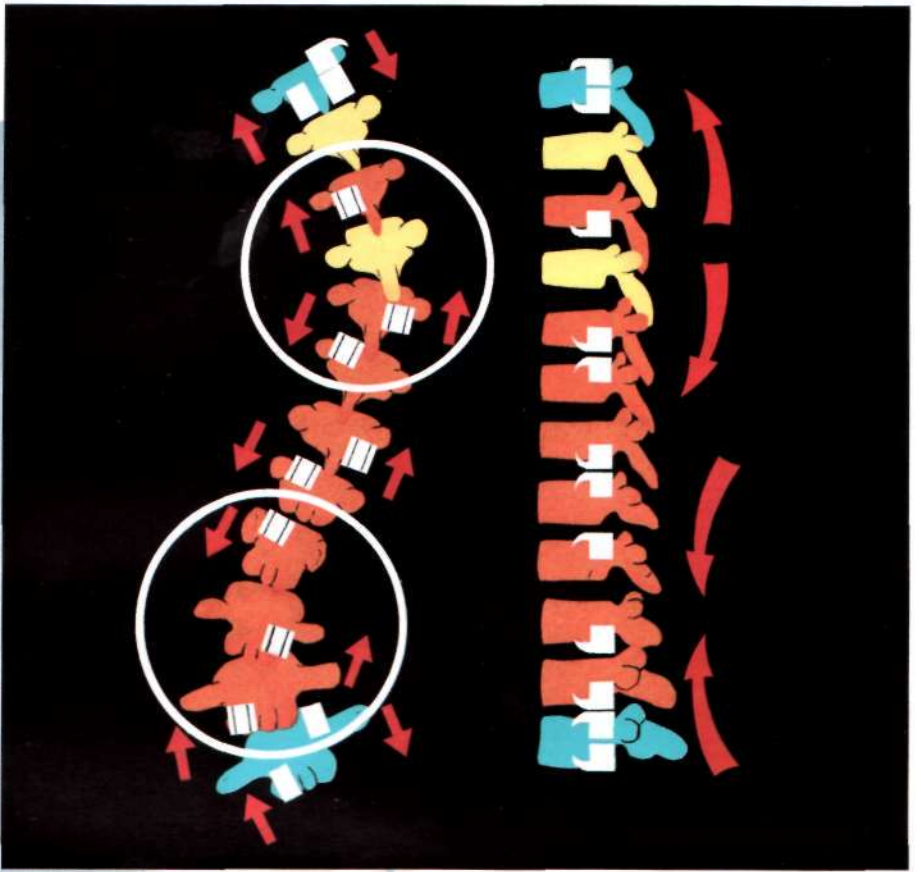
35b



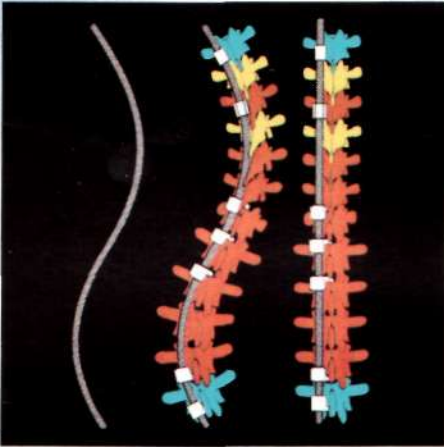
36a



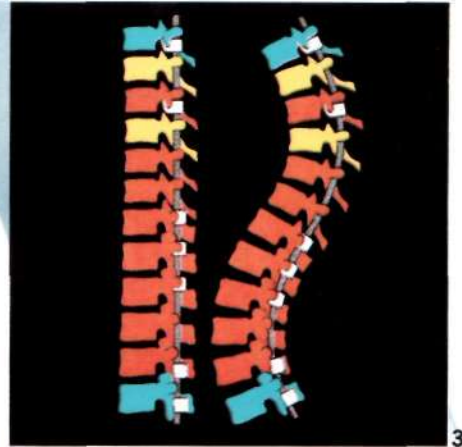
36b



37



38



39

(Thoracic and lumbar).

Distraction or compression direction forces can be applied at any point on the same rod simply by changing hook direction (37). Rod bending should approximate normal physiologic contours. Rod rotation in a direction away from the spine simultaneously corrects the frontal plane, and the additional sagittal and axial planes, thus affording three-dimensional correction of each curve (38,39).

With large and/or stiff curves, in either the frontal or sagittal plane, each curve may require individual and separate correction. The first side of each curve is corrected with a single rod, the rods are connected with either a domino or an axial connector. It is then preferable to have on the other side of the spine one continuous rod without connectors.

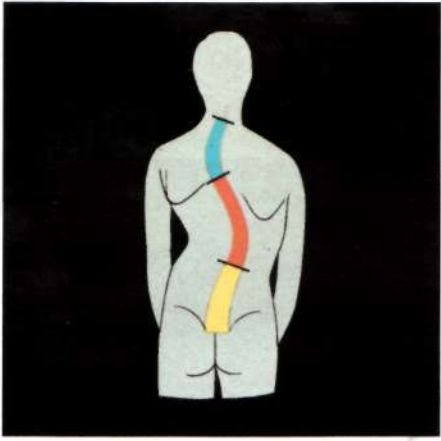Double major scoliosis (thoracic and thoracic (40))

There are several possibilities:

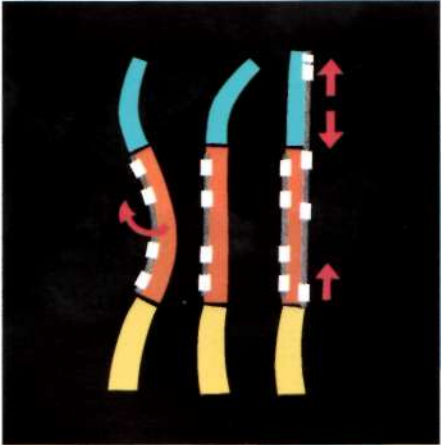
A temporary rod may be placed in the concavity of the lower thoracic curve and rotated (41). Subsequently, a long rod is placed on the convexity of the lower curve (concavity of the upper curve), bent to normal sagittal contours. This corrects the upper curve, and completes instrumentation of the lower curve while restoring the normal contour of the instrumented area (42). The temporary rod can then be removed and replaced with a long rod, or the short rod may be extended with one of the connecting devices. A temporary rod is extremely helpful in the situation where there are two frontal curves in the same sagittal segment (as double thoracic curves) and also where there is one frontal curve over two sagittal curves.



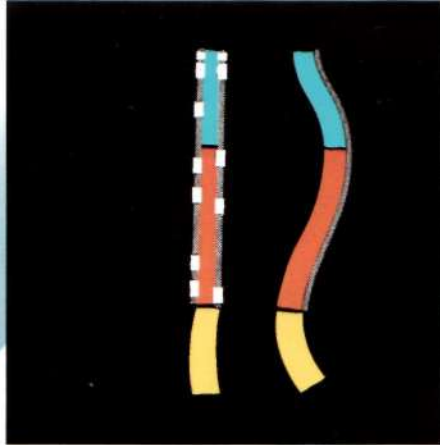
40



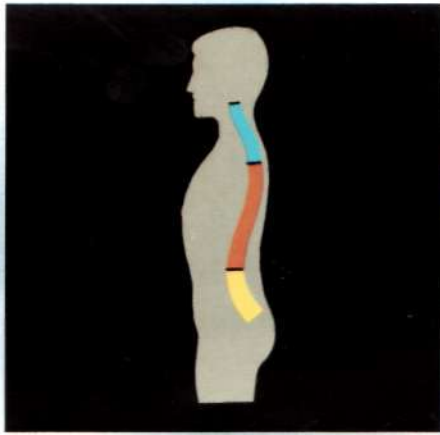
41a

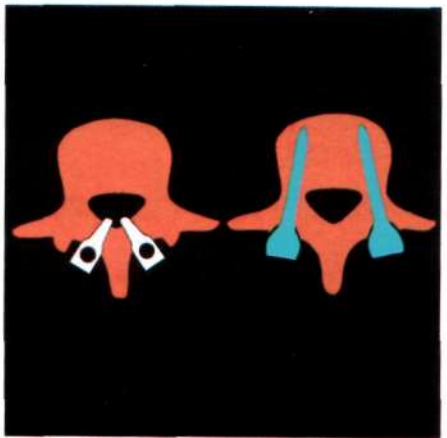
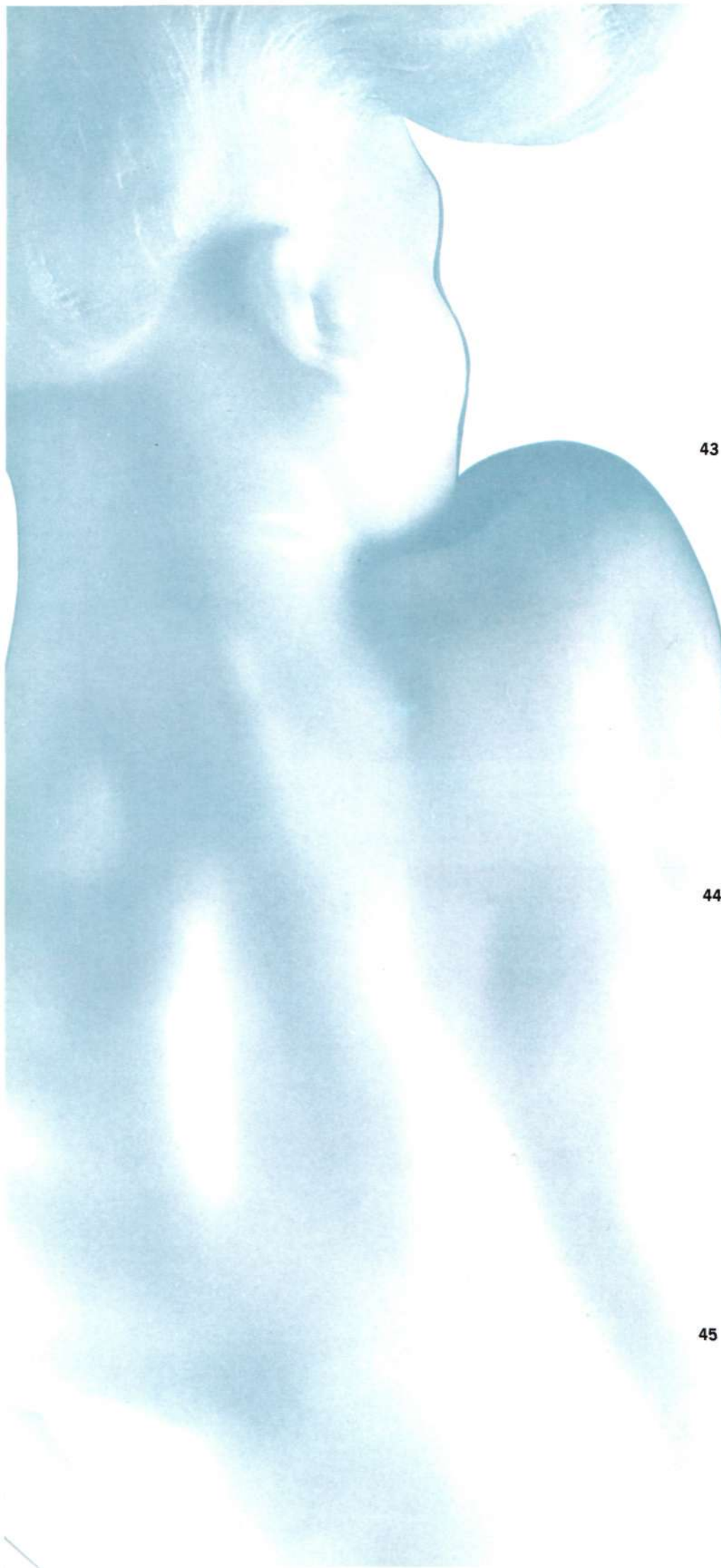


41b



42





43



44



45

Lumbar scoliosis.

The general rules above stated have to be applied. Nevertheless, some specific points need to be recall.

On the lumbar vertebrae, the lever arm of the C.D. grip, fastened by hooks, is quite short in the axial plane; it is also medial and posterior to the rotation axis of the lumbar spine. A more lateral and anterior fixation, closer to the vertebral rotation axis, will provide a longer and more efficient lever arm.

It is accomplished by implantation of screws inside the pedicles to the vertebral body (43).

Two screws placed in the same lumbar vertebra, inside the pedicles, forwardly convergent and posteriorly connected by a transverse device (D.T.T. (44) or Chopin plate (45)) features a triangular construct in the axial plane providing the vertebral fixation a greater stability in the three dimensions.

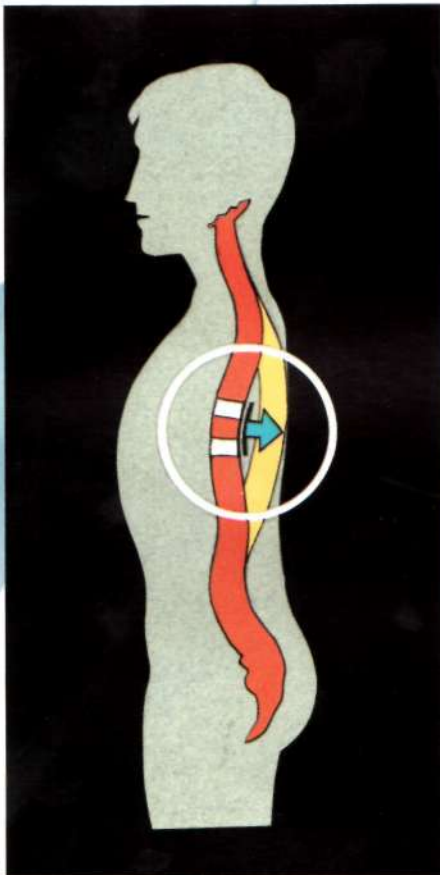
One must be cautious to carefully observe the spine when rotating the rod in the above screw configuration, as translation of the spine may occur instead of the desired rotation.

Ten technical guidelines for use of the C.D.

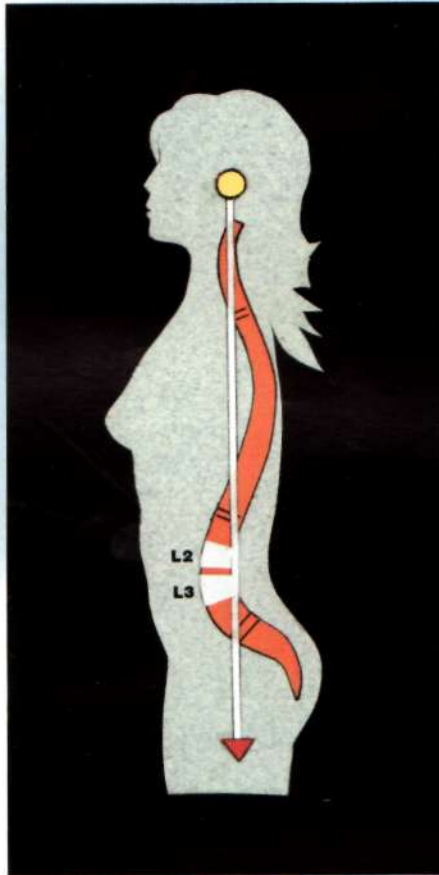
in scoliosis.

1. Always determine the end vertebrae by analysis of standing lateral film. E.V. defined on the AP film are only temporary.
2. Always instrument all E.V. with closed implants. Intermediate vertebrae, I.V. are usually instrumented with open implants.
3. Always instrument the E.V. bilaterally, in opposite directions in scoliosis.
4. Always place a claw on the upper E.V., at least on the convex side in scoliosis (and always on both sides in kyphosis).
5. Always place an implant at the apex of the convex side.
6. Always design the implant configuration and load it to open the closed disc spaces and to close the opened disc spaces.
7. Always restore the sagittal alignment as near as possible to normal. This may require variation in placement of the lower I.V. hook in lordotic thoracic scoliosis, in order to place this hook as close to the apex of the lordosis as possible (46).
Remember, the apex of normal lumbar lordosis is the L2-3 interspace. The sagittal weight bearing axis should fall posterior to the vertebral body of L2 and L3 (47).

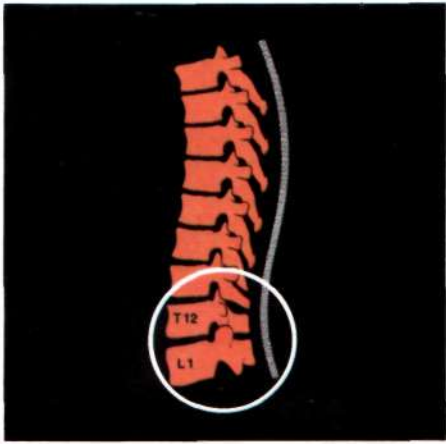




46



47



48



49



8. Always initiate the change in rod bending from kyphosis to lordosis at the T12-L1 interspace (48).
9. Always place two DTT devices, as close to the ends of the construct as possible (49).
10. Never forget the need of meticulous spinal fusion. No metallic device will survive the lack of spinal fusion.

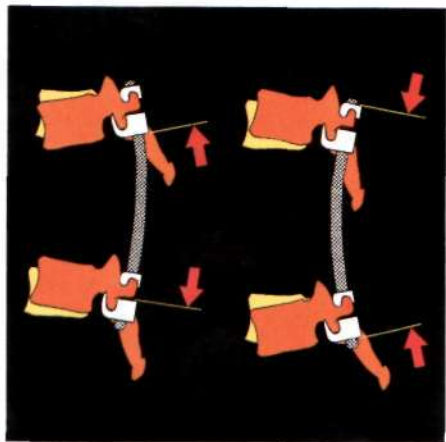
APPROACH TO A SINGLE DIMENSIONAL DEFORMITY

(pure kyphosis or lordosis).

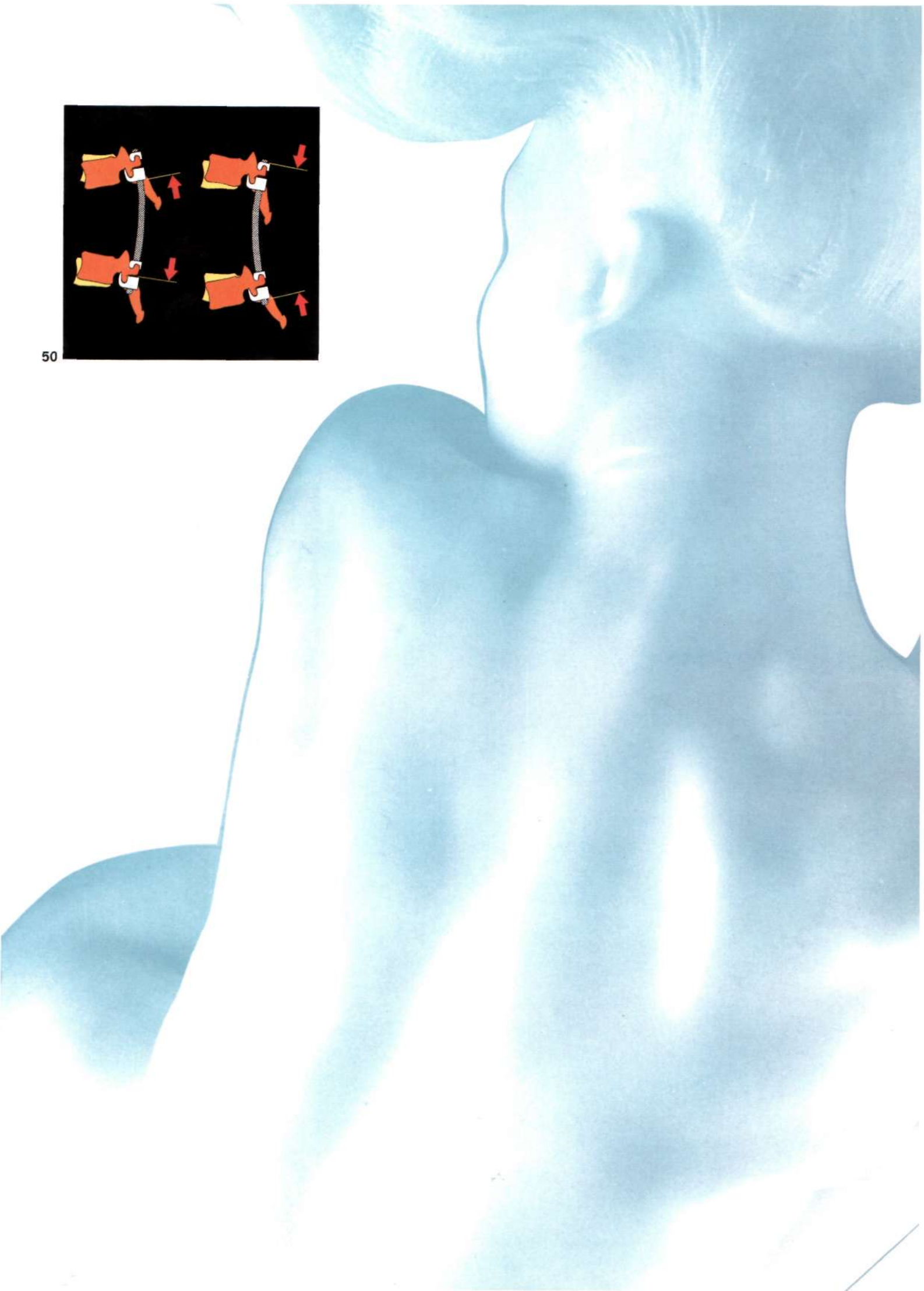
With pathology in a single plane regardless of the etiology (fracture, tumor, infection, Scheuerman's disease, or other), the strategy is simpler than with the previous examples. The corrective forces will be applied in only the sagittal plane.

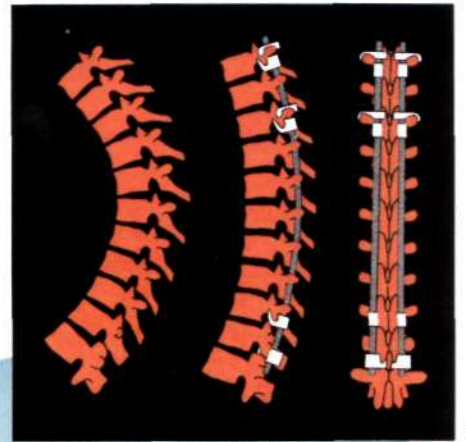
These forces can be adapted to act in the three dimensions, if there is accompanying frontal plane abnormalities. In general, symmetrical bilateral instrumentation and forces will be applied.

To produce absolute or relative kyphosis (or a lordotic deformity), the forces must be divergent relative to the apex. In the most frequent situation, to produce or to maintain lordosis (or to correct kyphotic deformity), the forces must be convergent to the apex (50).



50





50b

Long thoracic kyphosis or thoracolumbar kyphosis

(Scheuerman's kyphosis is the prototype).

It requires instrumentation over the whole of the kyphosis, extending to normal segments both above and below (50b). Usually, this is to T-1 or T-2 above, and to L-1 or L-2 below. In thoracolumbar Scheuerman's condition, L-3 is required. In neuromuscular deformity, the distal extent is frequently to the sacrum.

Technically, in surgery of kyphotic deformities, the interspinous ligament must be preserved on both extremities. If destroyed, junctional kyphosis may occur, producing imbalance in the sagittal plane.

In kyphosis, vertebral fixation requires a minimum of two, and preferably three, long constructs, **bilateral claws**, both above and below the apex.

C.D. permits placement of claws at any level. (51)

These are:

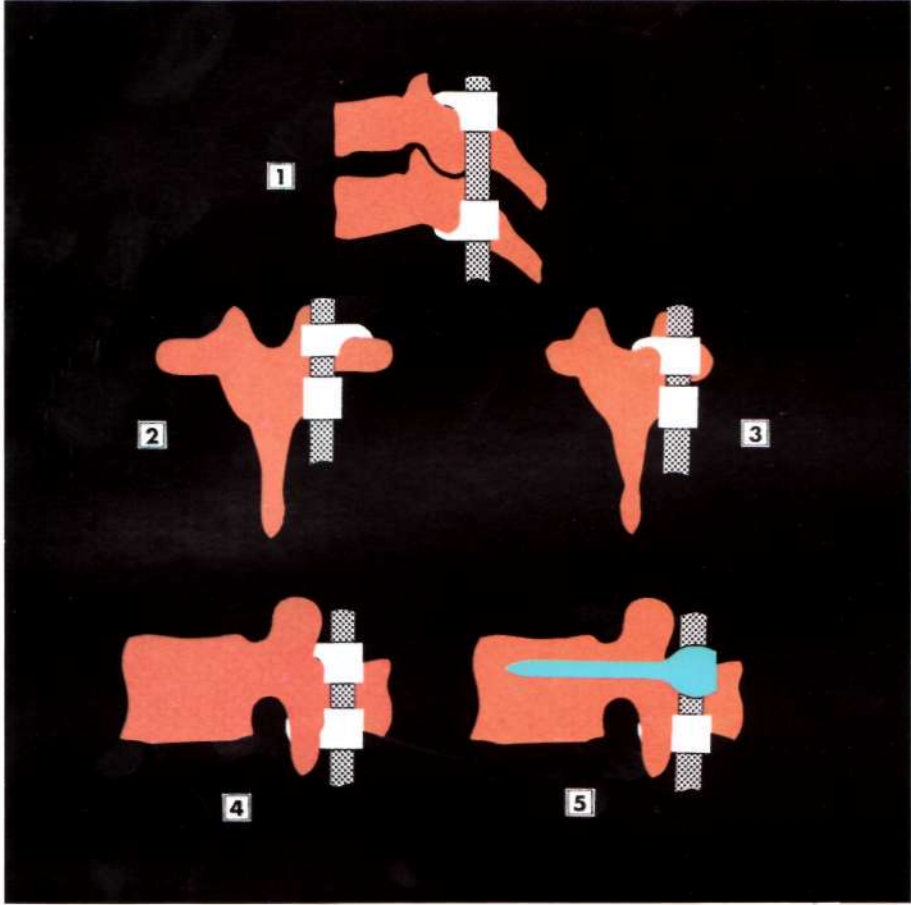
- cervical lamino-laminar claw (51/1),
- thoracic pediculo-transverse claw (51/2),
- thoracic pediculo-laminar claw (51/3),
- lumbar lamino-laminar claw (51/4),
- lumbar lamino-pedicular claw (51/5).

These claws are one of the most original features of the C.D.I.

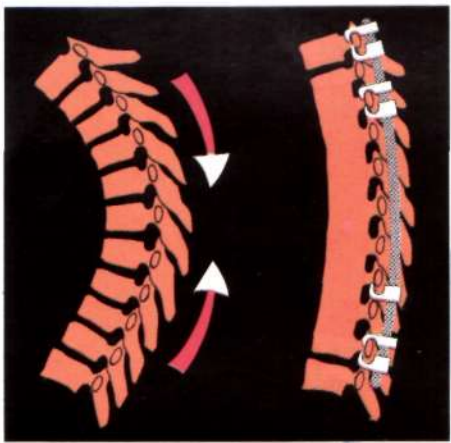
They can be uni or bivertebral according to the bone quality and the strength of the corrective forces.

These multiple grips insure a very stable vertebral fixation. This is most important at the ends of sagittal plane deformities. These grips impart sagittal rotary control to each segment of the spine that is instrumented.

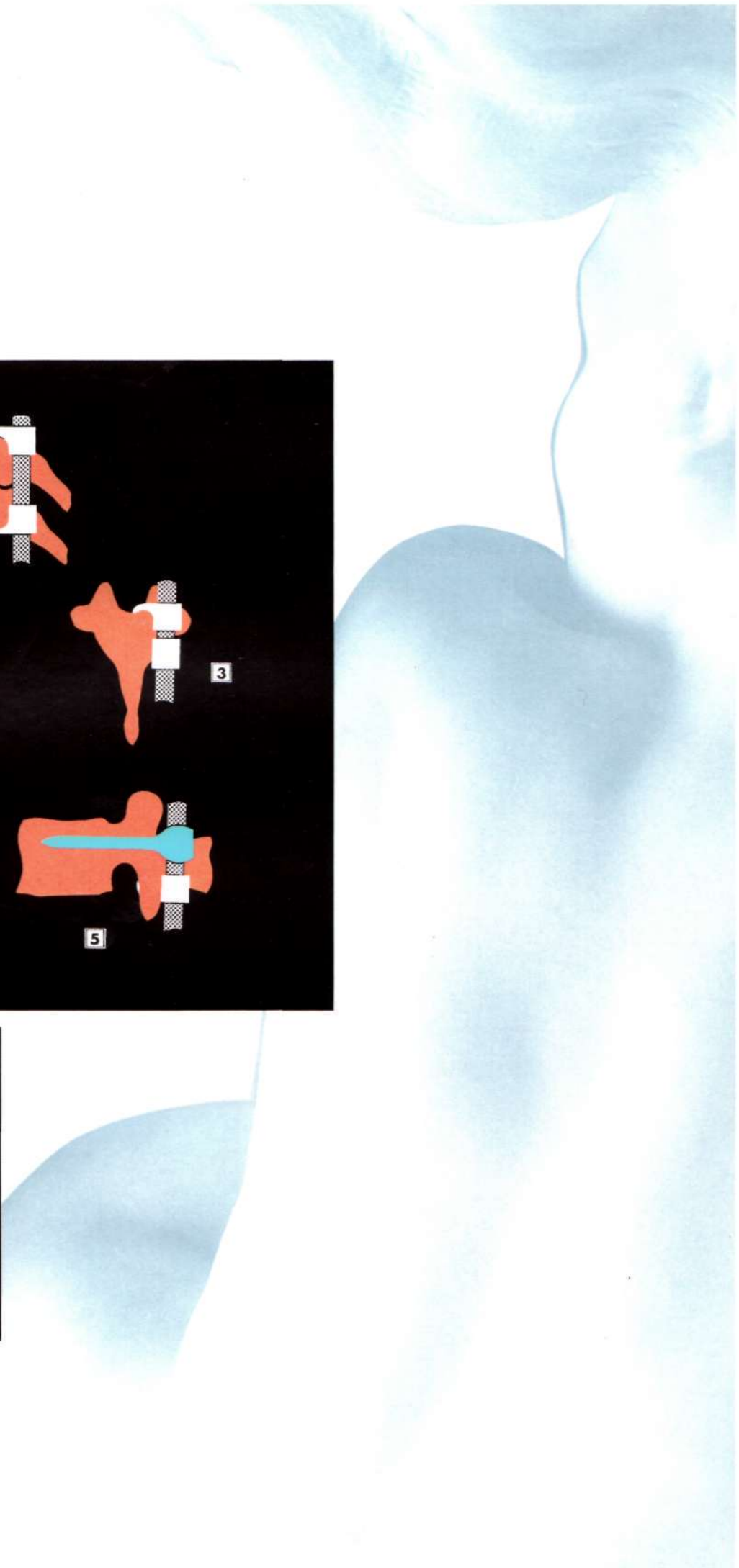
If correction of a kyphotic deformity results in a significant anterior opening of one or more interspaces, consideration of anterior interbody fusion may be necessary (52).

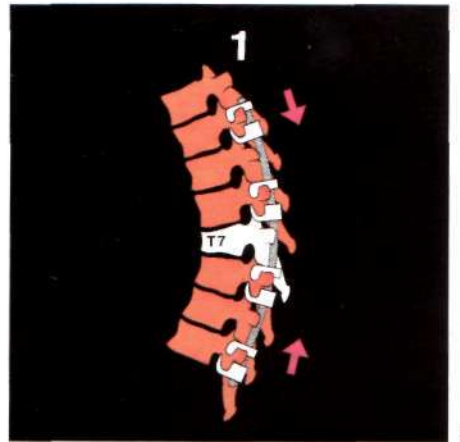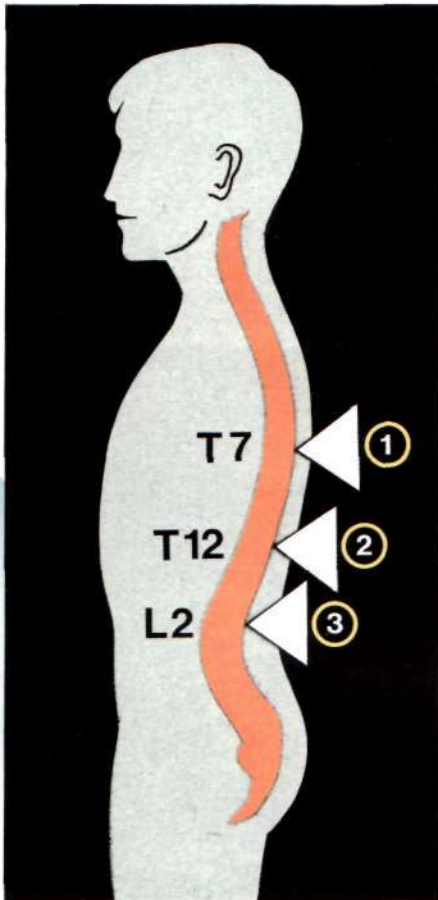


51

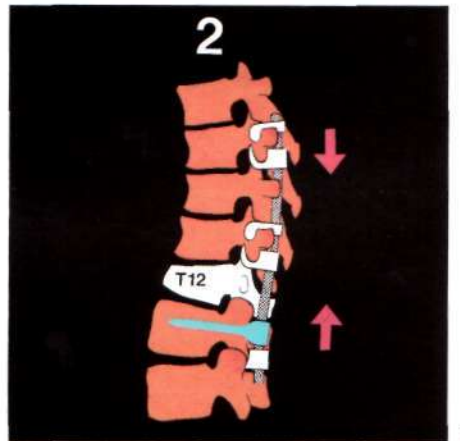


52





53



54



55

Short deformities in kyphosis.

These are usually due to anterior injuries, e.g. fracture, tumor, or infection. The strategy will vary according to the particular pathology and spinal level, but, the same principles and hook patterns apply. The exception is that the instrumentation will be shorter.

General rules for instrumentation of short kyphotic segments according to the spinal level:

Thoracic spine. (53)

The instrumented segment must be long, over the whole kyphotic segment. Thus, a strong posterior tension band is created, preventing, in most situations, any anterior collapse. Any significant anterior gap should be treated to restore the anterior continuity and prevent a secondary instability.

Thoracolumbar junction. (54)

Proximal extension into the thoracic spine can be done, without deleterious effect. Nevertheless, extension into the distal lumbar spine should be avoided when it is possible. Equal lever arms relative to the apex of the kyphosis should be attained, to decrease the stress on the shorter lever arm. The double grip with screws and hooks on the lumbar lower vertebra may permit reduction by one level, of the extent of the instrumentation.

Lumbar spine. (55)

Instrumented segments should be as short as possible, thereby preserving lumbar spine motion.

The pedicle screws are most beneficial in the lumbar

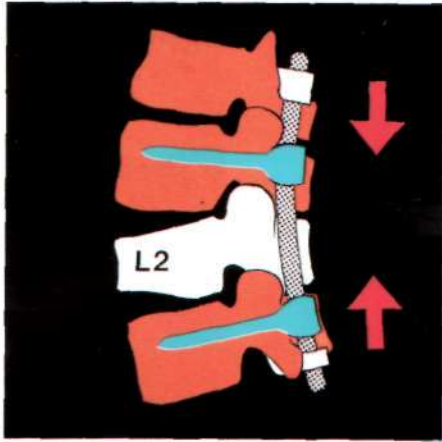
spine. They offer a total bilateral vertebral fixation, from the back to the front, very stable and allowing short constructs. Pedicle screws can be protected against the direct flexion forces by hooks placed on the same rod, above and below. These hooks will prevent the pull-out of the screws. Then, the rigidity of the construct decreases from the screws to the hooks (56).

Protection proximal to the screws.


This protection is ensured by the offset body hooks inserted in a supralaminar position on the upper vertebra. Then, the vertebral interspace will act as a damper. Additional lordosing forces can be obtained by approximation of these hooks to the screws, moving to the back the weight bearing axis.

Protection distal to the screws.

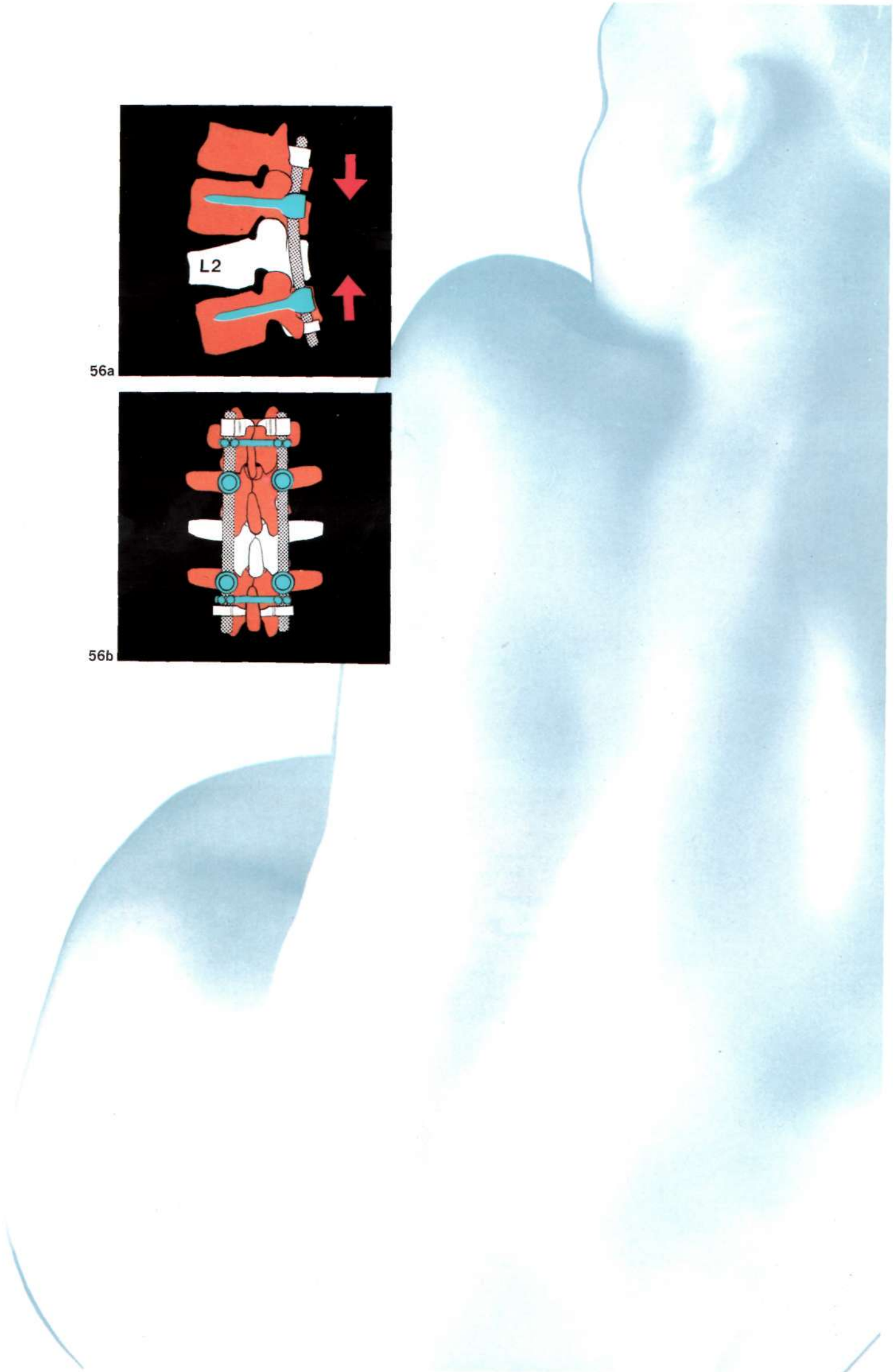
This protection is ensured by the infralaminar insertion, on the same vertebra, of either, the offset body hooks or the hooks with a lengthened and oblique blade. Biomechanically, with double fixation of screws and hooks on the same vertebra, stability is significantly enhanced. This is important in the elderly with poor bone. No postoperative external support is required in most instances.

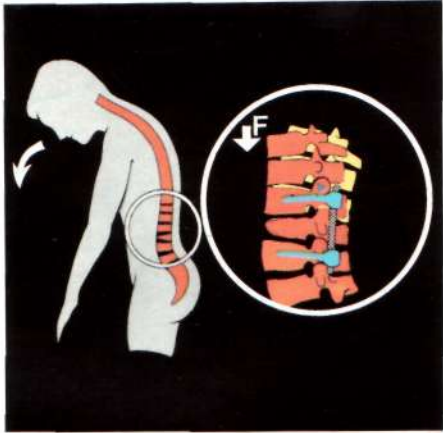

56a

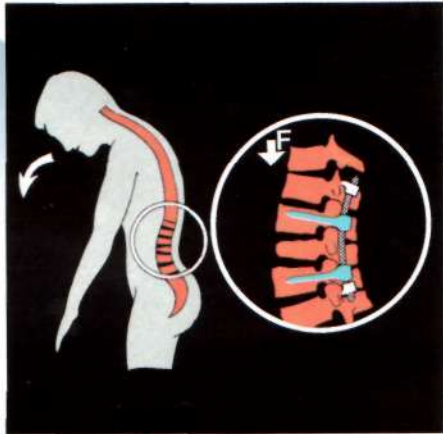

56b

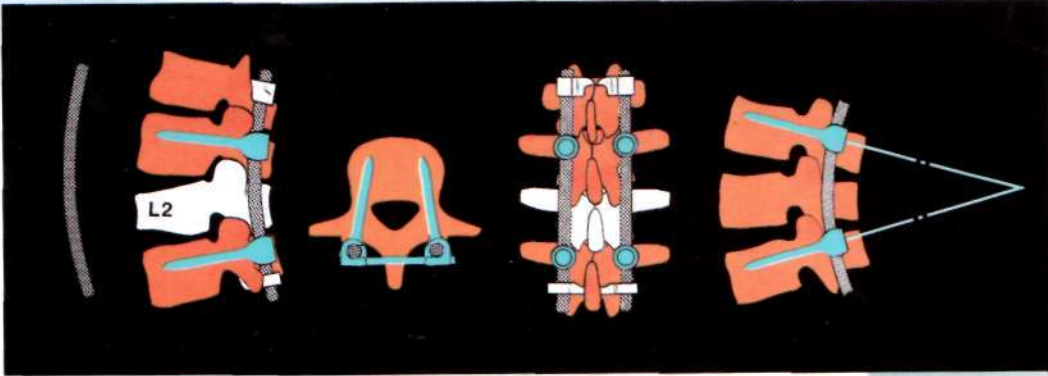




57a



57b



58

1

2

3

4

5

Advantage of protective hooks (57).

In anterior flexion of the trunk, cantilever bending forces are imparted to anterior part of the most proximal implants. In case of screws, they will eventually bend and break. With a hook above, the screws are “protected”, as there is always micromotion between hook and lamina. The forces of cantilever bending are not directly transmitted to the rigid screw, but to the hooks having a lower fixation rigidity.

The risk of pull-out or fatigue fracture of the screws

is reduced in the following steps (58):

1. Adequate lordotic rod-bending placing the sagittal weight bearing axis posterior to the implants, applying compressive rather than distractive forces.
2. Hooks placement above or (and) below screws.
3. Triangular construct in the axial plane.
4. Rectangular construct in the frontal plane.
5. Triangular construct in the sagittal plane.

The pull-out of the screws being thus prevented, the mechanical resistance to the cantilever forces can be increased by lengthening the neck and widening the core diameter, which are the characteristics of the C.D. screws.

Although screw-rod fixation in C.D. is very rigid, flexibility remains, due to the use of rods with alternatives in term of resistance and elasticity (59).

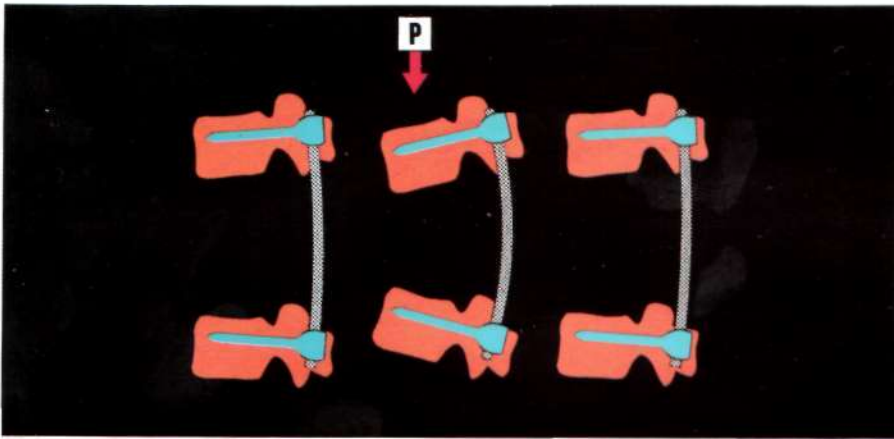
Variable diameters and metallurgical characteristics impart four different types of rod:

- 1) 5.5 mm standard rod,
- 2) 5.5 mm cold rolled rod,
- 3) 7 mm standard rod,
- 4) 7 mm cold rolled rod.

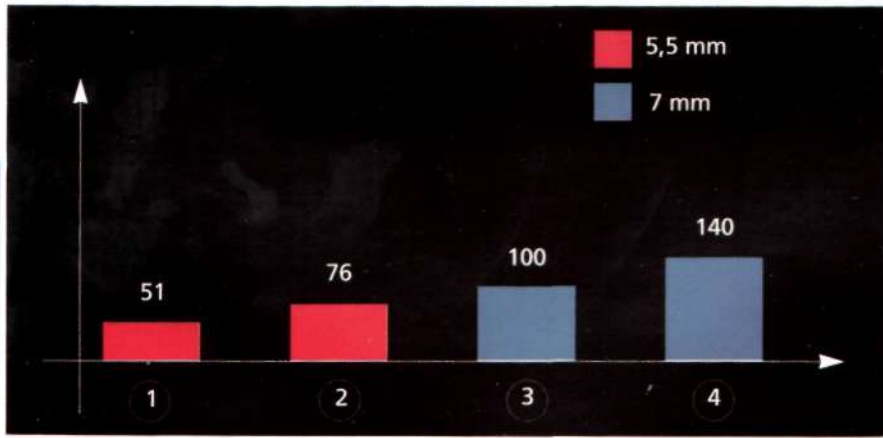
Biomechanical tests show that the elastic limit of the cold rolled rods is significantly increased, compared to the standard rods. Because of the higher limit of elasticity of the rod, the risk of secondary deformation or breakage is reduced.

Nevertheless, regardless of the strength of the implants, if a solid arthrodesis is not performed, failure will occur. This mandates principles learned long ago, careful facet refreshing, meticulous decortication and copious bone grafting. With residual three dimensional instability, particularly kyphosis with a loss of bone substance or excessive enlargement of the disc spaces, consideration for anterior fusion must be given. Additionally, do not hesitate to immobilize the patient with an external device if there is any question of competency of the instrumentation.

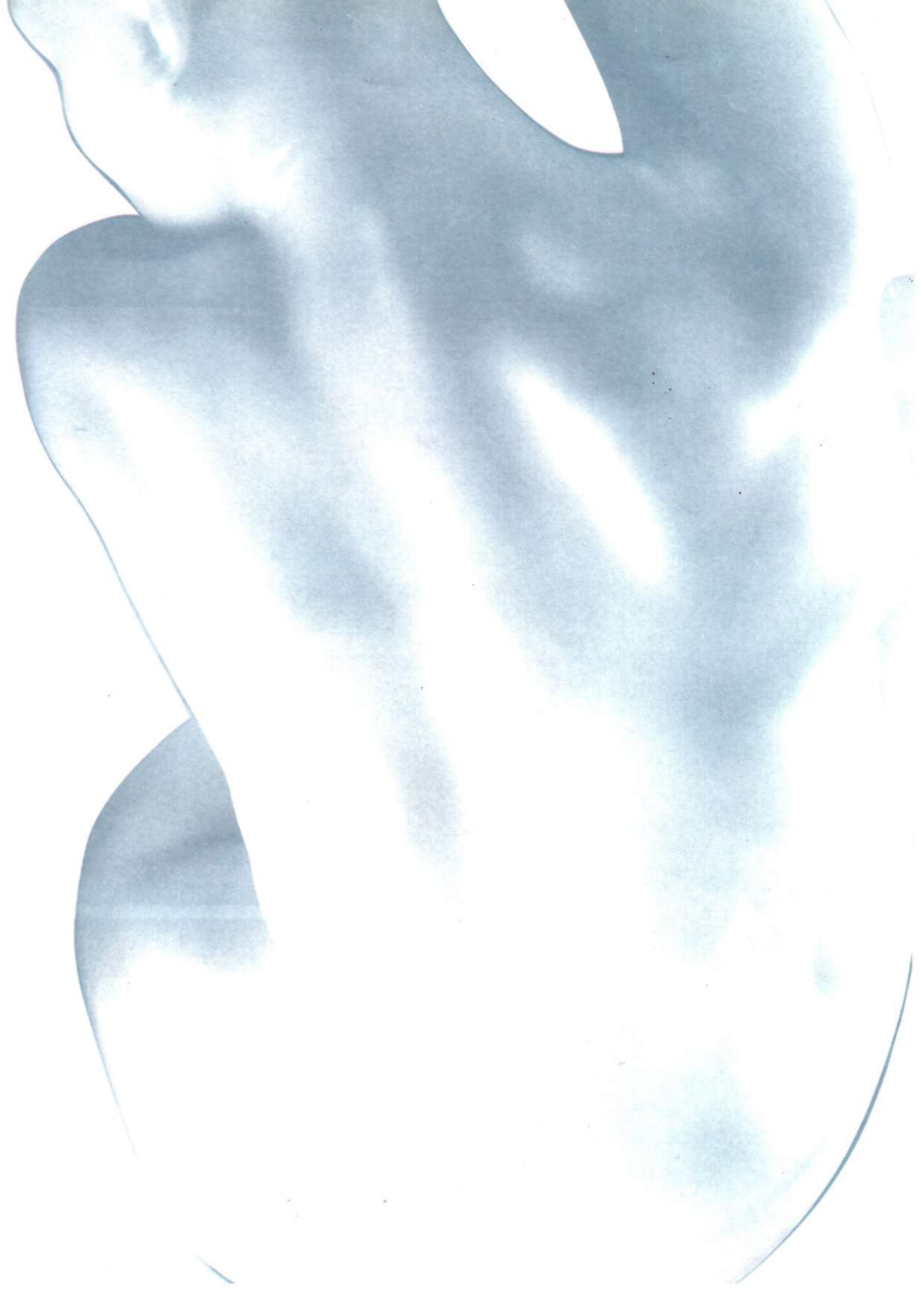




59



60



Conclusion

It is my hope at the end of this presentation that the basic principles of the C.D. Instrumentation are evident and should lead to better understanding and more secure and efficient care of the patient in whom correction and stabilization of the spine is required.

Remember the following three points:

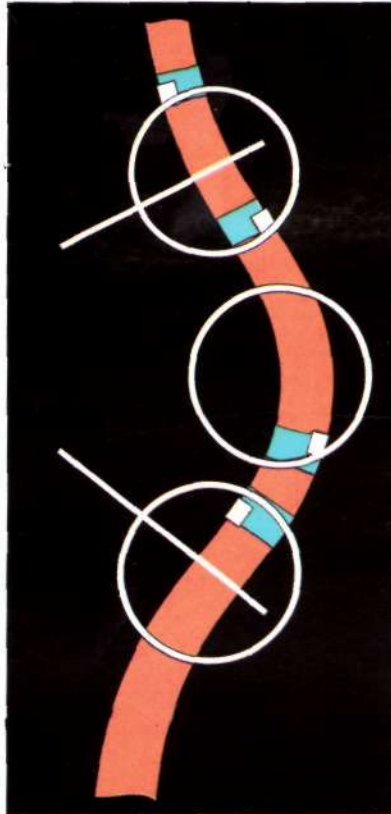
- With C.D.I. or any spinal instrumentation, regardless of the etiology of the deformity or of the instability, **restoration of the sagittal anatomy is the most basic and necessary requirement.**
- The spine must always be considered from a **three dimensional** point of view in the analysis of its disorders, as well as in their treatment.
- “Every case is **individual**, and the surgery must be planned in the brain of the surgeon before to be performed in the back of the patient”.

STRATEGIC MISTAKES

The most usual strategic mistakes in CDI have been the following ones:

MISTAKE 1

Incorrect strategic vertebrae.

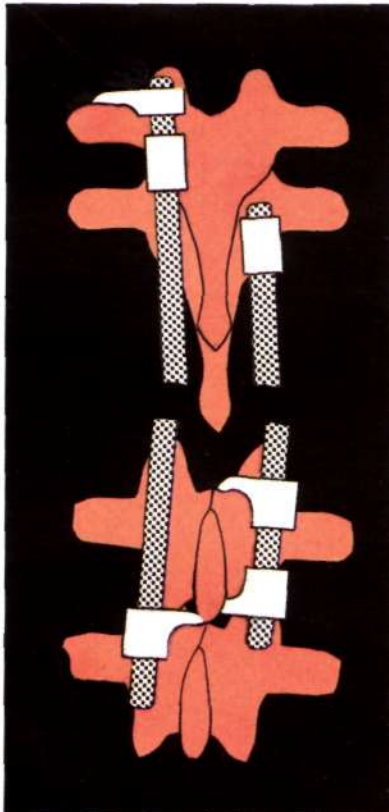


RESULT

- Poor sagittal reconstruction
- Inadequate correction
- 3-D imbalance.
- Possible deformity increase.

MISTAKE 2

End vertebrae without bilateral instrumentation.





RESULT

- Poor coronal E.V. horizontalization.
- Unstable E.V. fixation.

MISTAKE 3

Open hooks on E.V.



RESULT

- Risk of dislodgment of blocker and rod.

MISTAKE 4

No PT claw on convex U.E.V. in scoliosis.

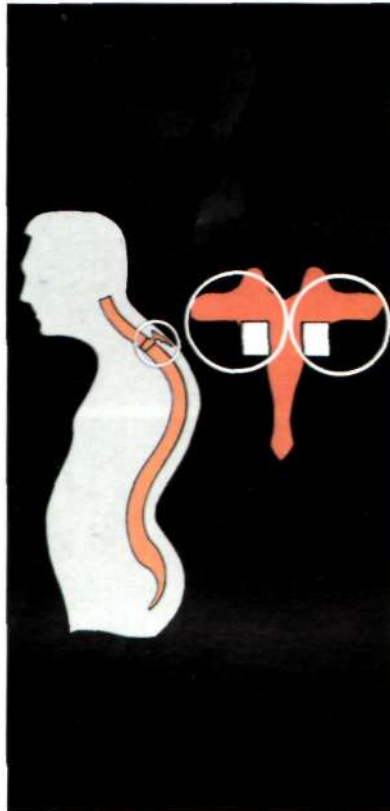

RESULT

- Disengagement of U.E.V. with forward bending.
- Impossible convex compression.
- Medial displacement of pedicle hook (no transverse hook).
- Transverse process fracture (no pedicle hook).

MISTAKE 5

No bilateral PT claw of U.E.V. in kyphosis.




RESULT

- No sagittal rotary control.
- Risk of hook dislodgment in anterior bending.
- No correction possible by proximity to the E.V.

MISTAKE 6

Apical vertebrae not instrumented in scoliosis.




RESULT

- No detorsion.
- No segmental fixation.
- Increase in possible rotation.

MISTAKE 7

No instrumentation of I.V.




RESULT

- No correction of rigid area.
- No sagittal reconstruction.
- No spinal detorsion.

MISTAKE 8

Instrumentation of I.V. in same direction.



RESULT

- No concave apical opening.
- No sagittal reconstruction.
- Unstable situation (Loading one implant, unload the other).

MISTAKE 9

Force direction distally opening spaces already open (distraction on convexity of lumbar segment).

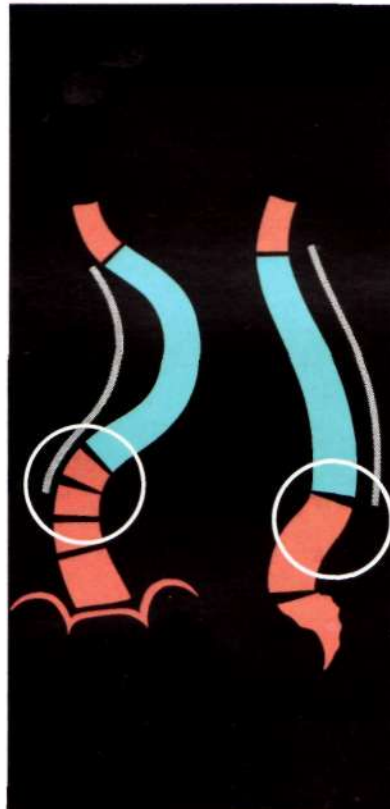

RESULT

- Increase in opening of space.
- Coronal decompensation.
- No sagittal reconstruction.

MISTAKE 10

Ending instrumentation in middle of pathologic curve.

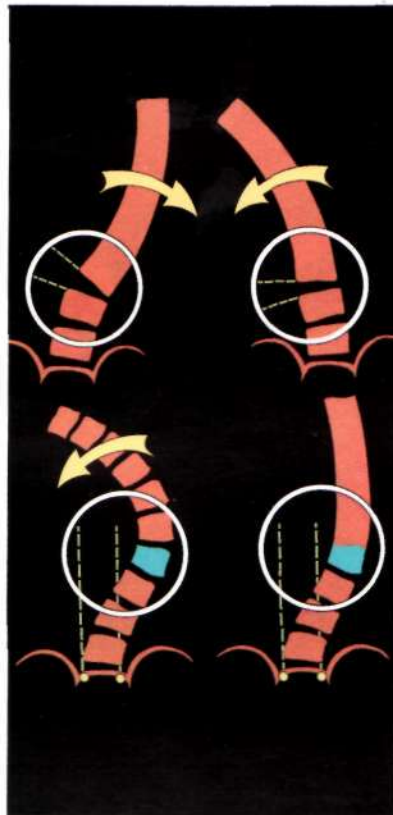


RESULT

- Coronal or sagittal decompensation.

MISTAKE 11

Ending on a LEV whose disc fails to open both sides in frontal and sagittal plane, or is out of stable zone on bending films.



RESULT

- Coronal and sagittal decompensation.

MISTAKE 12

Ending on LEV with large residual rotation.



RESULT

- Coronal and axial imbalance.

MISTAKE 13

Failure to include a pathologic sagittal deformity.

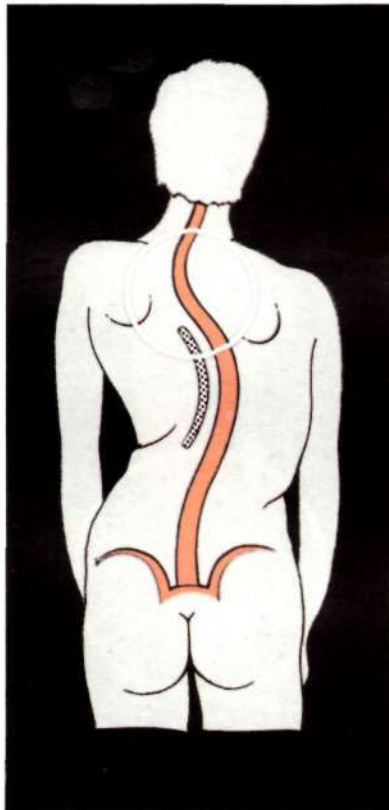


RESULT

- Progressive junctional sagittal deformity.

MISTAKE 14

Failure to include a high thoracic curve (until bending neutralization).




RESULT

- No change or increase of the upper curve.
- Elevation of shoulder.
- Coronal imbalance.

MISTAKE 15

Failure to include the sacrum in paralytics if no lumbosacral lordosis.

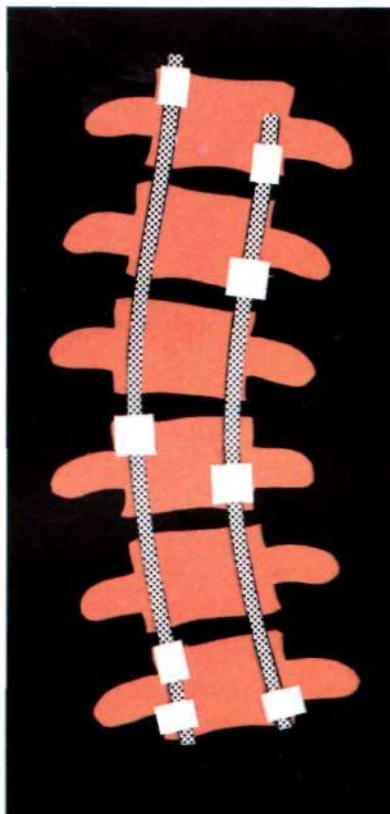


RESULT

- Progressive lumbosacral kyphosis.

MISTAKE 16

Failure to place 2 DTT's.

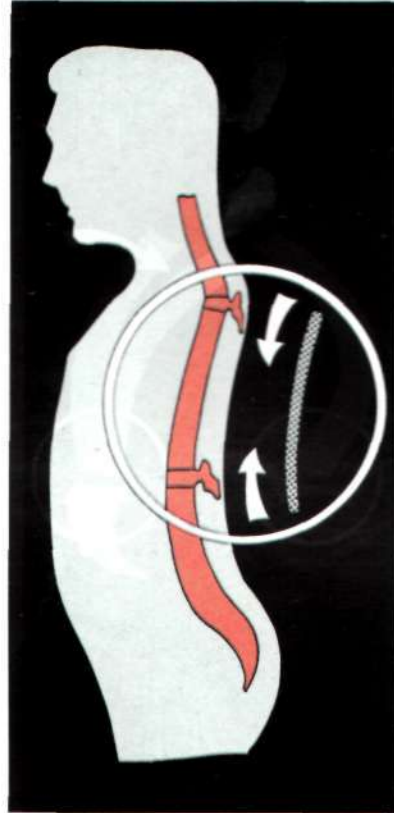


RESULT

- Unstable construct in torsion.
- Progressive possible deformity.

MISTAKE 17

Lordotic segment instrumented in compression.




RESULT

- Increase in lordosis.
- Increase in sagittal curves above and below.

MISTAKE 18

Kyphotic segment instrumented in distraction.

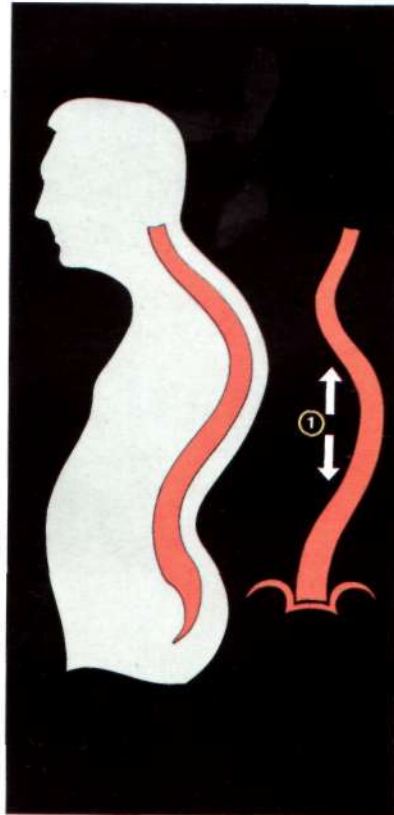


RESULT

- Possible neurologic injury.
- No kyphosis correction.
- Increase in sagittal curves above and below.

MISTAKE 19

In kyphoscoliosis, initial rod in concavity.

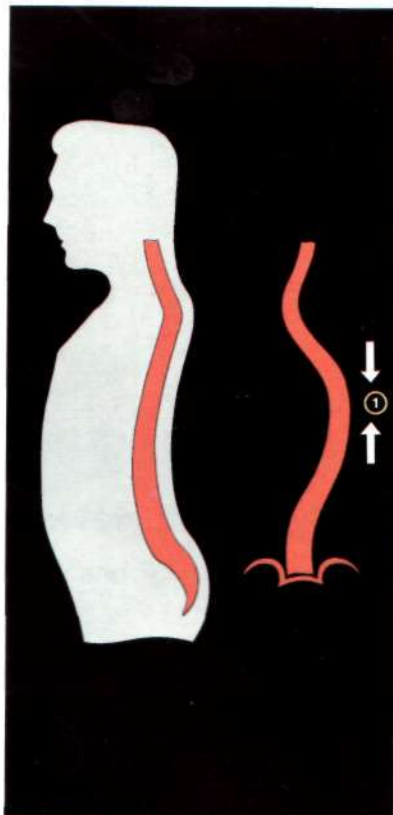


RESULT

- Neurologic injury.
- Lack of 3-D correction.

MISTAKE 20

In lordoscoliosis, initial rod in convexity.



RESULT

- Increase of lordosis.
- Lack of 3-D correction

*I would like to thank Harry Shufflebarger, M.D. for his collaboration
in the writing of this work and SOFAMOR for its contribution to its realization.*

Y. COTREL